

115

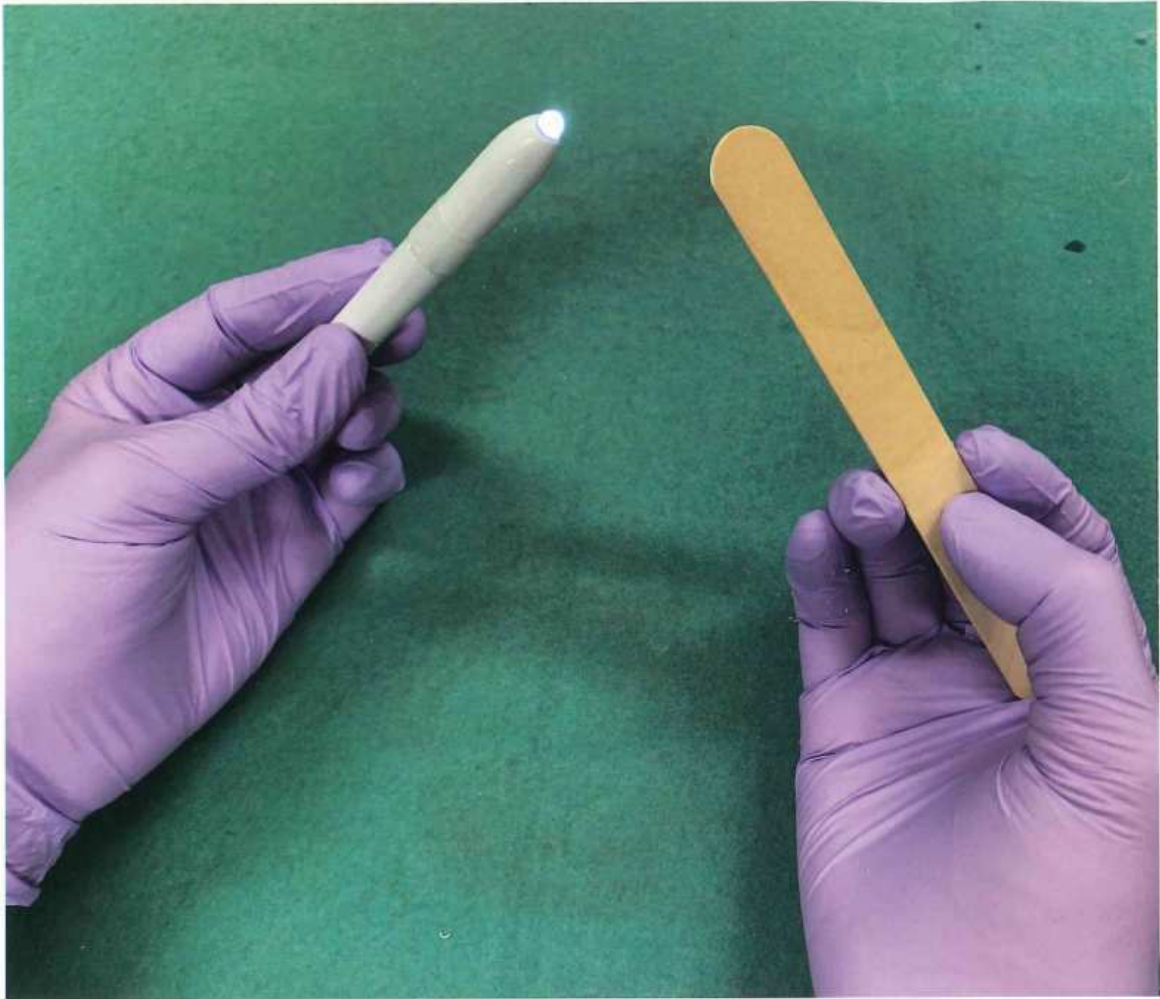
B

別 冊



No. 1

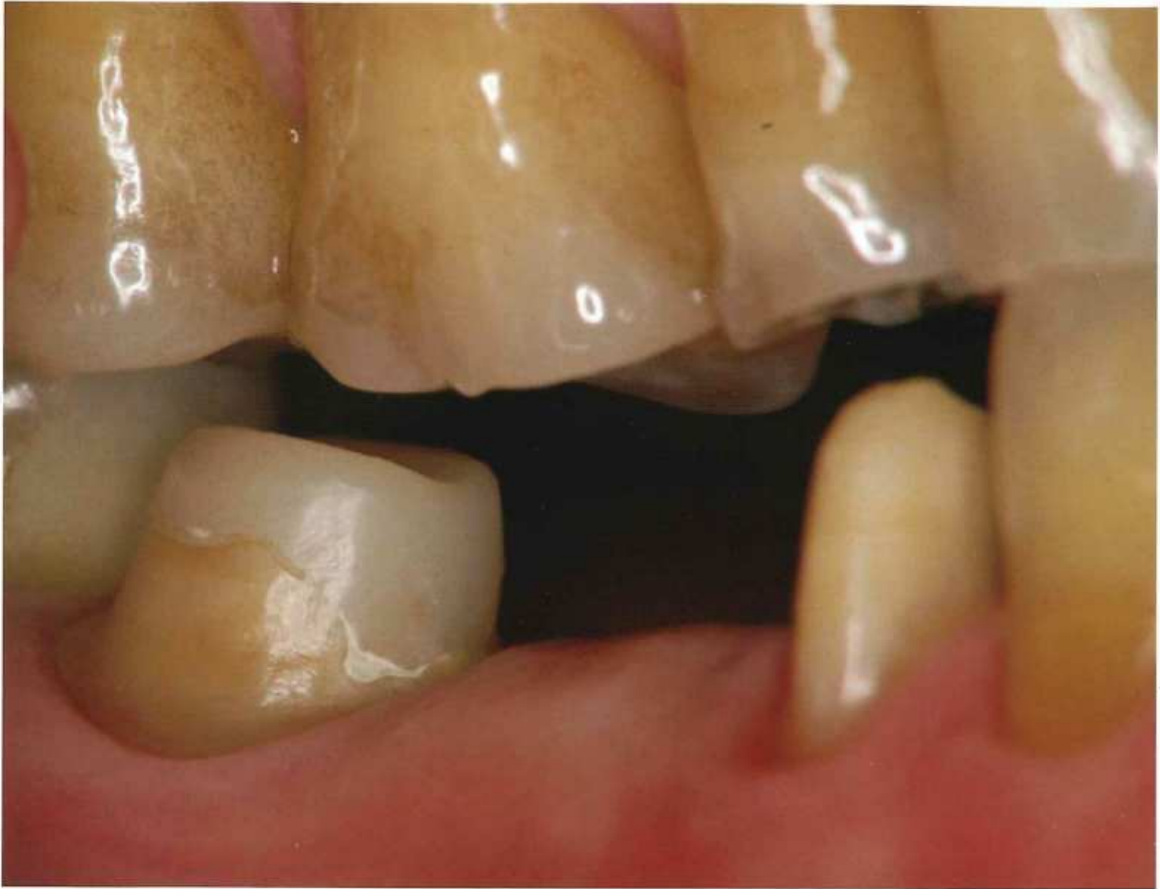(B 問題7)



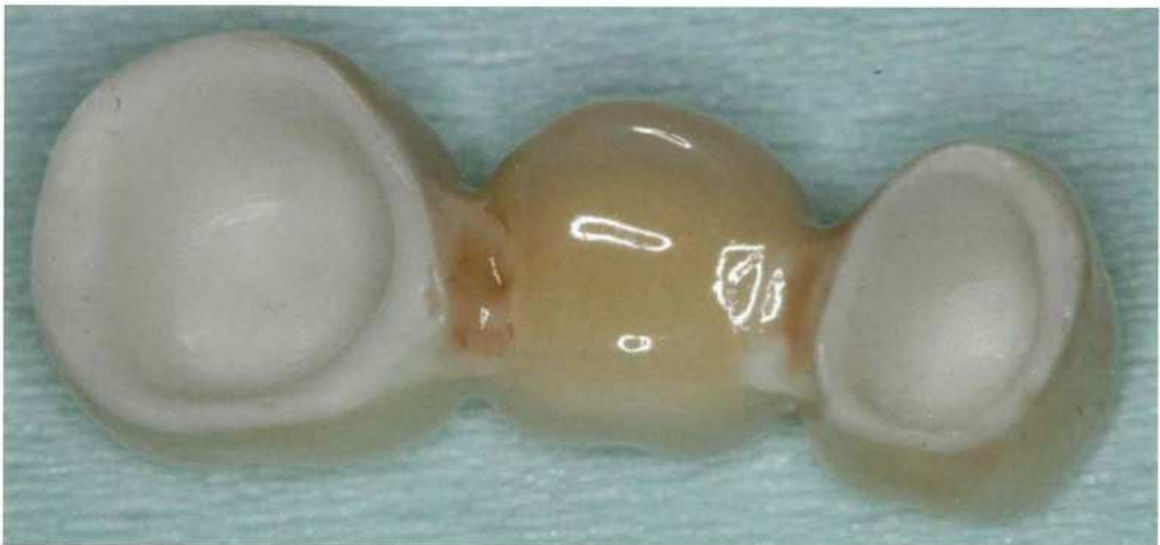No. 2

(B 問題 21)

A

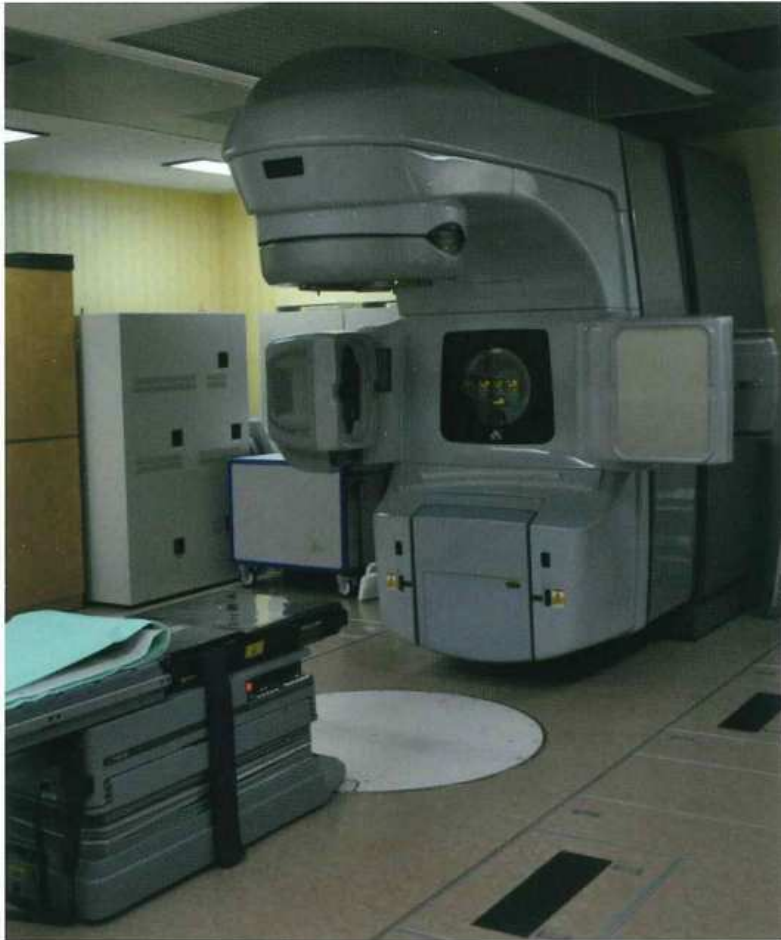

B

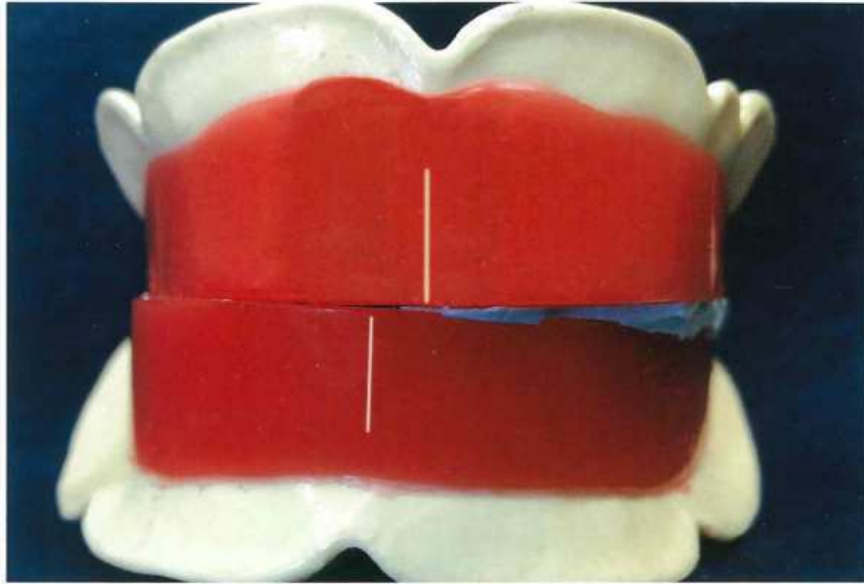


No. 3

(B 問題 23)

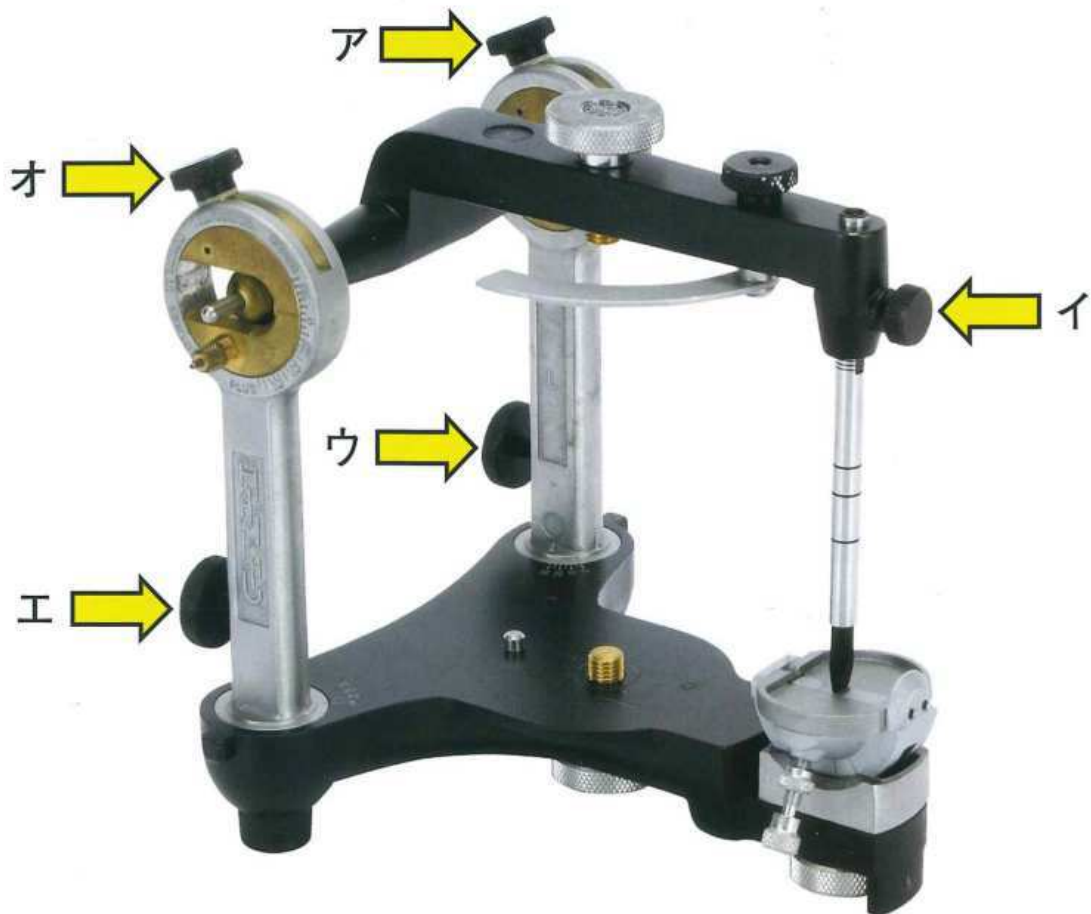


A



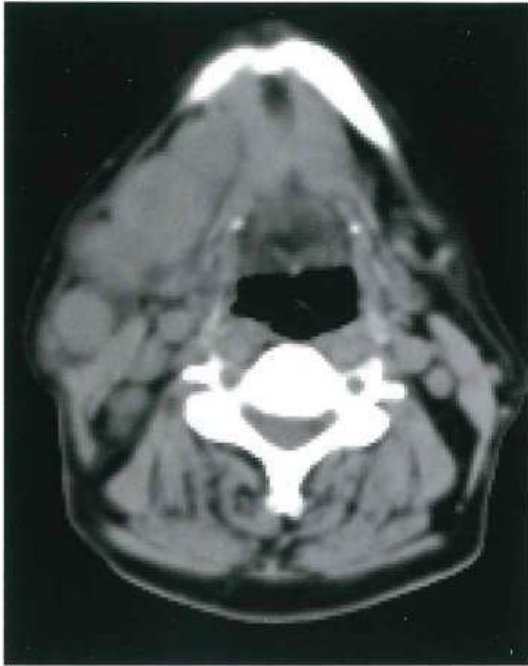咬合記録 (白線は正中線を示す)

B

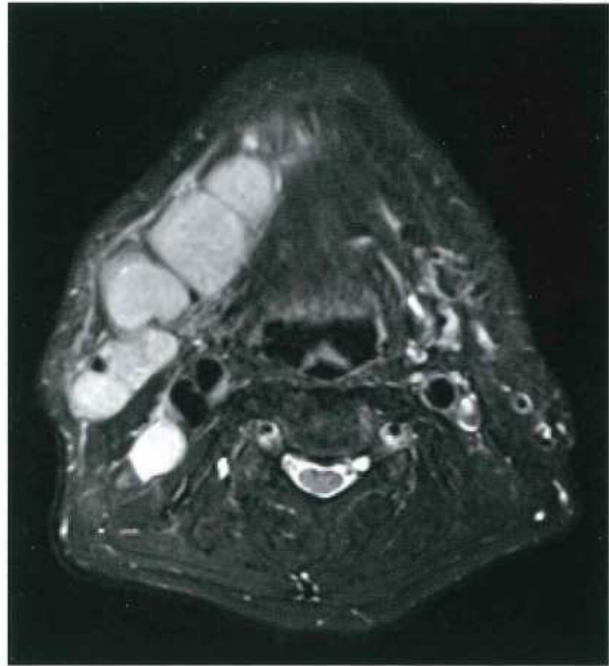

余 白

A

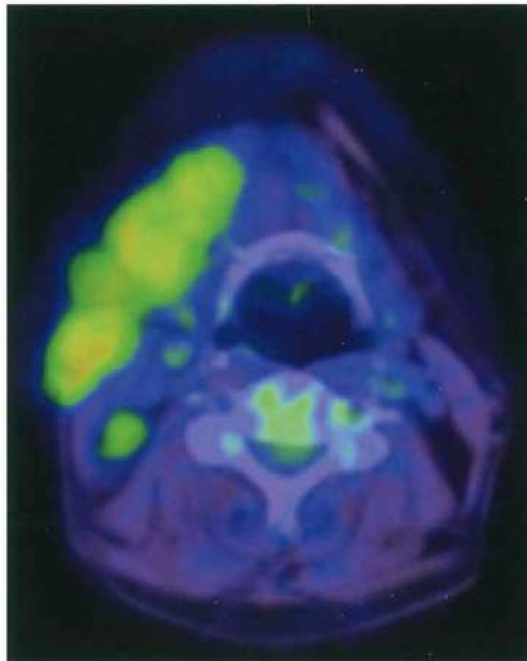


B



脂肪抑制 T2 強調像

C

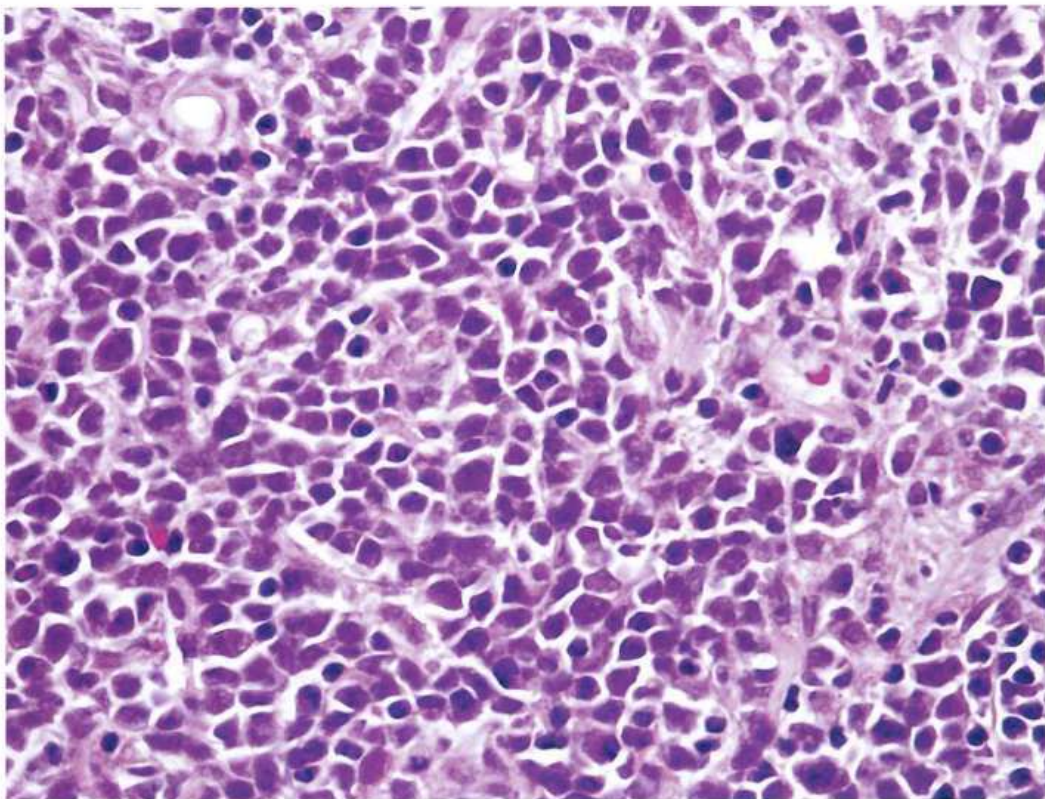
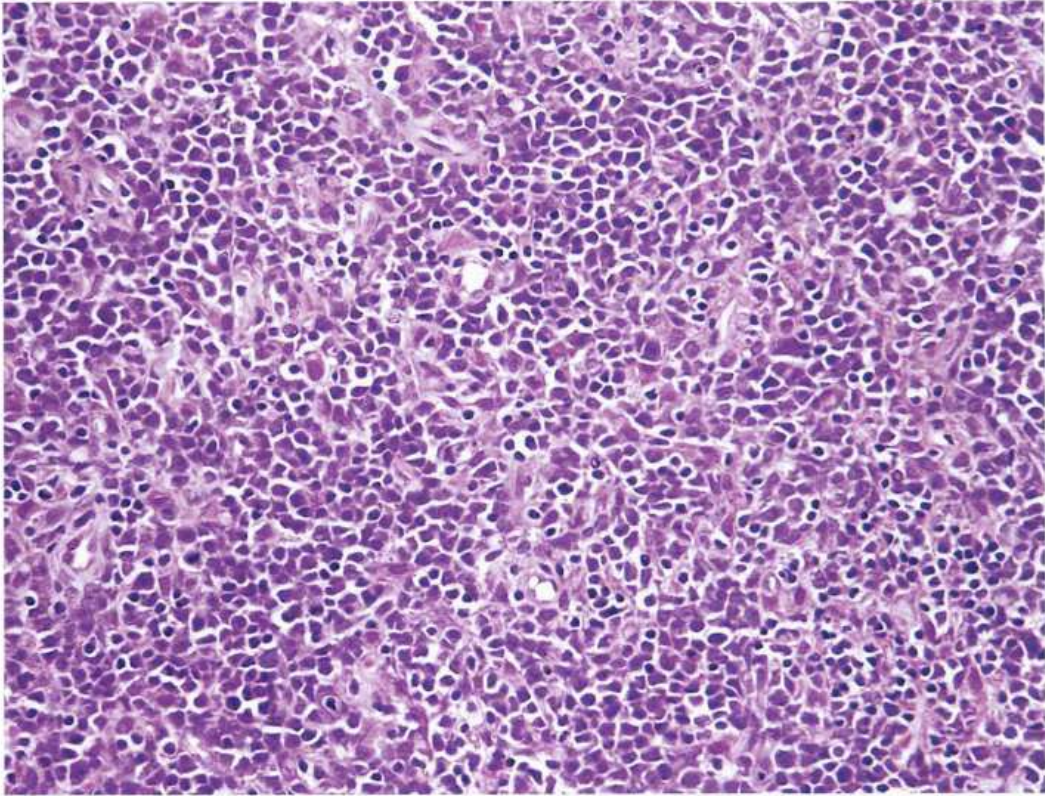


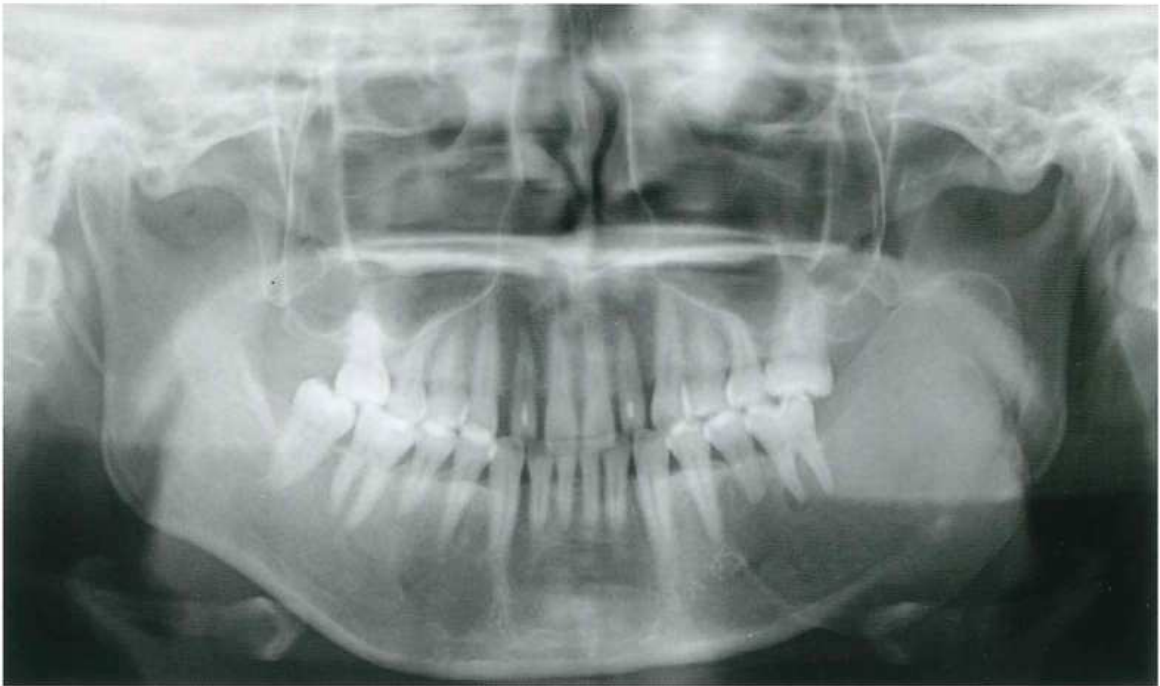


No. 5

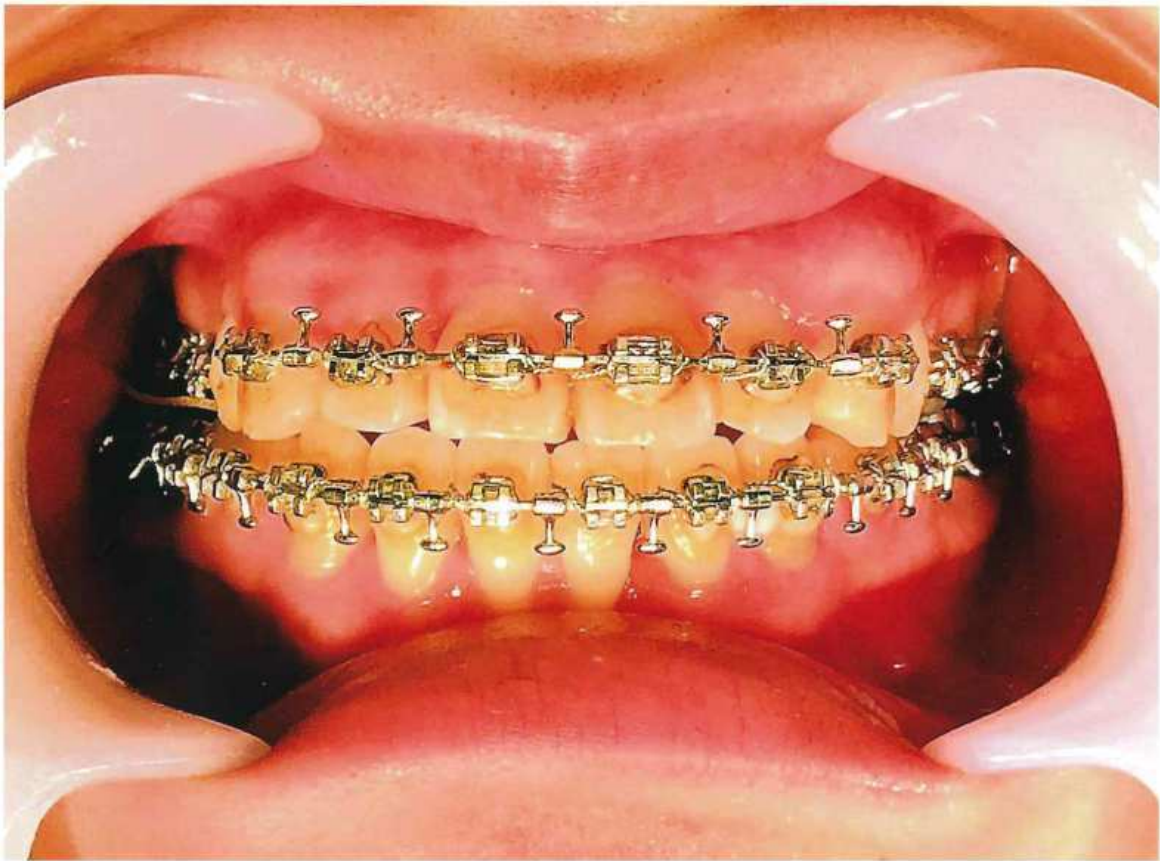
(B 問題 25)

D

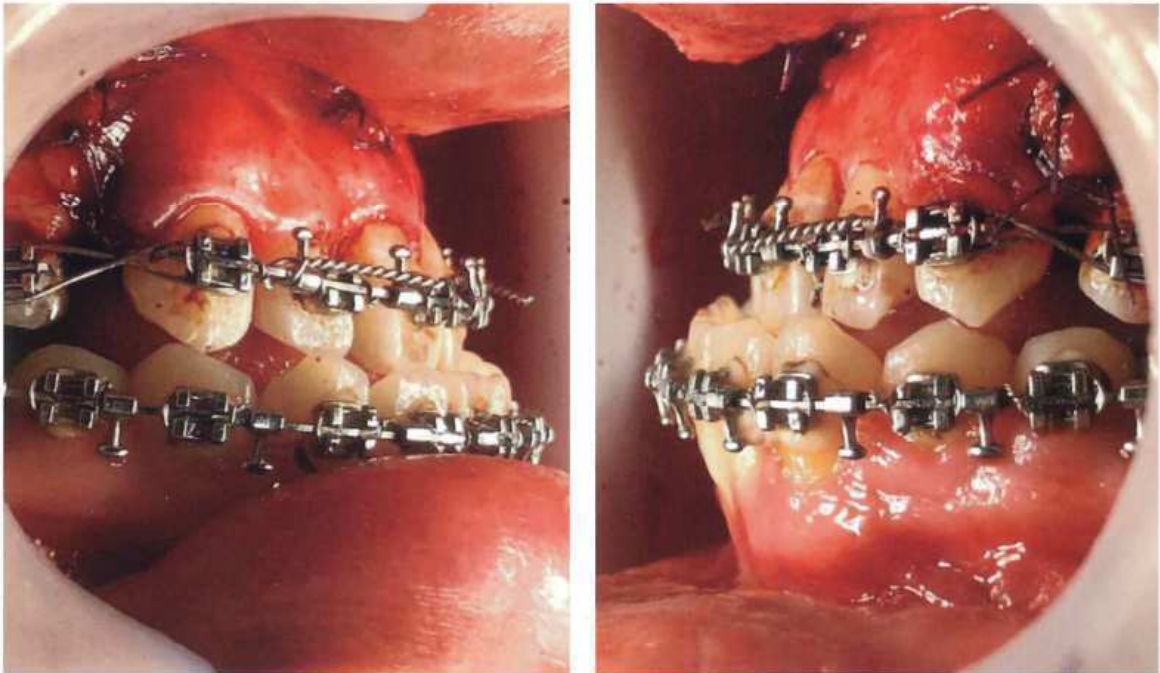




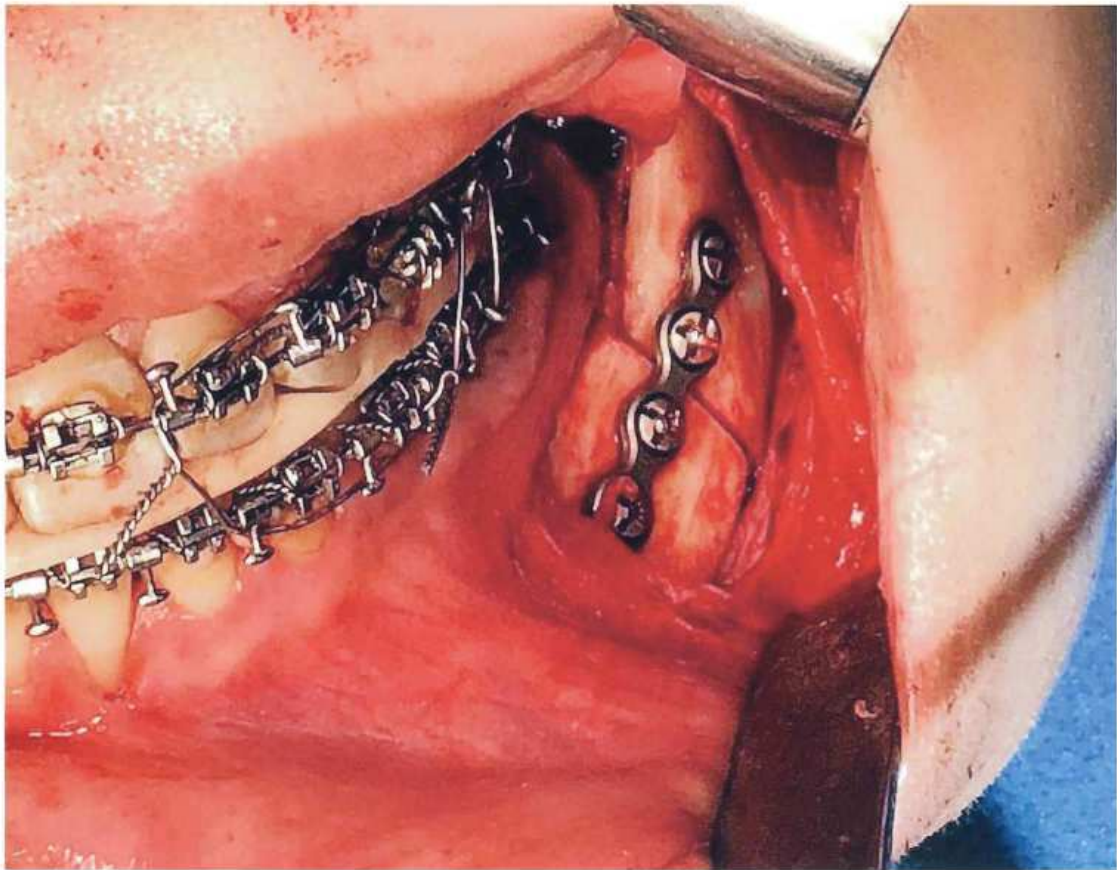
余 白



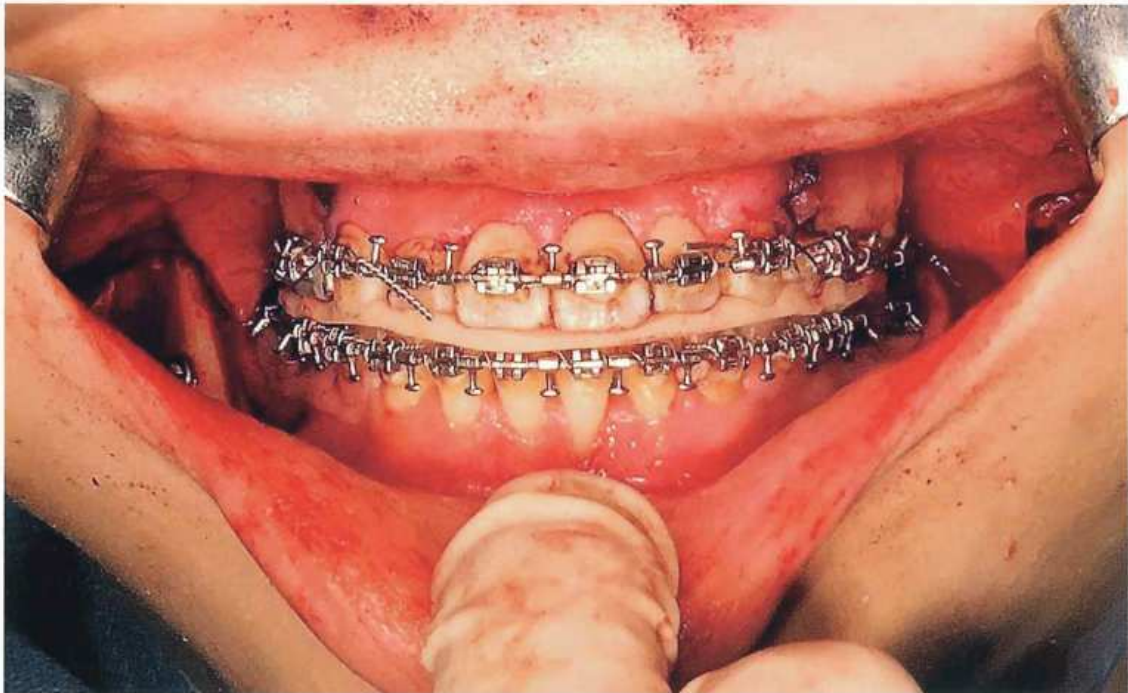術前



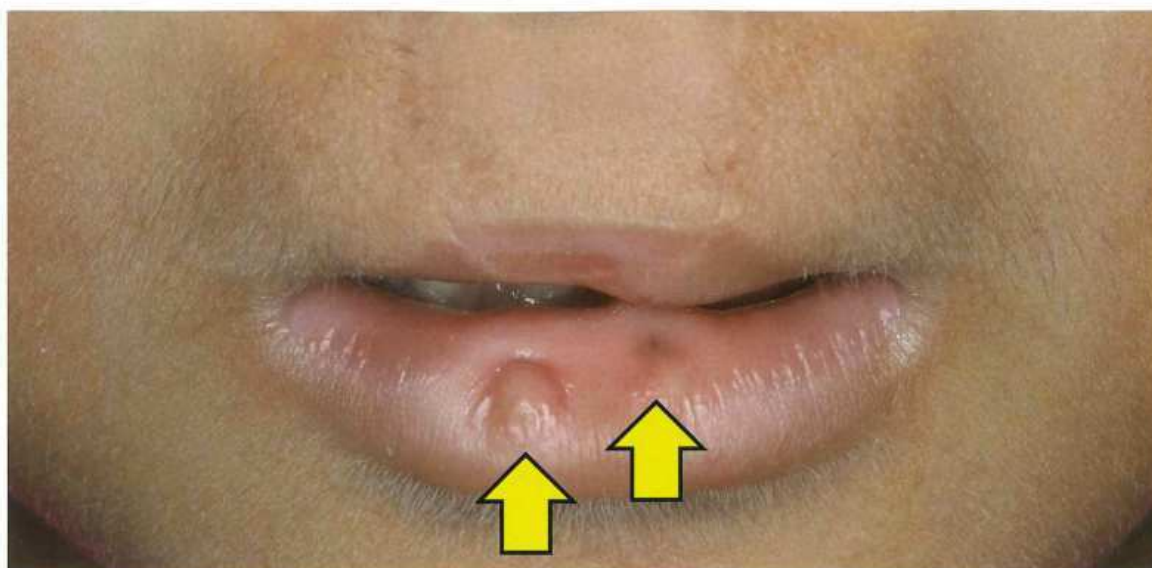
上顎移動後



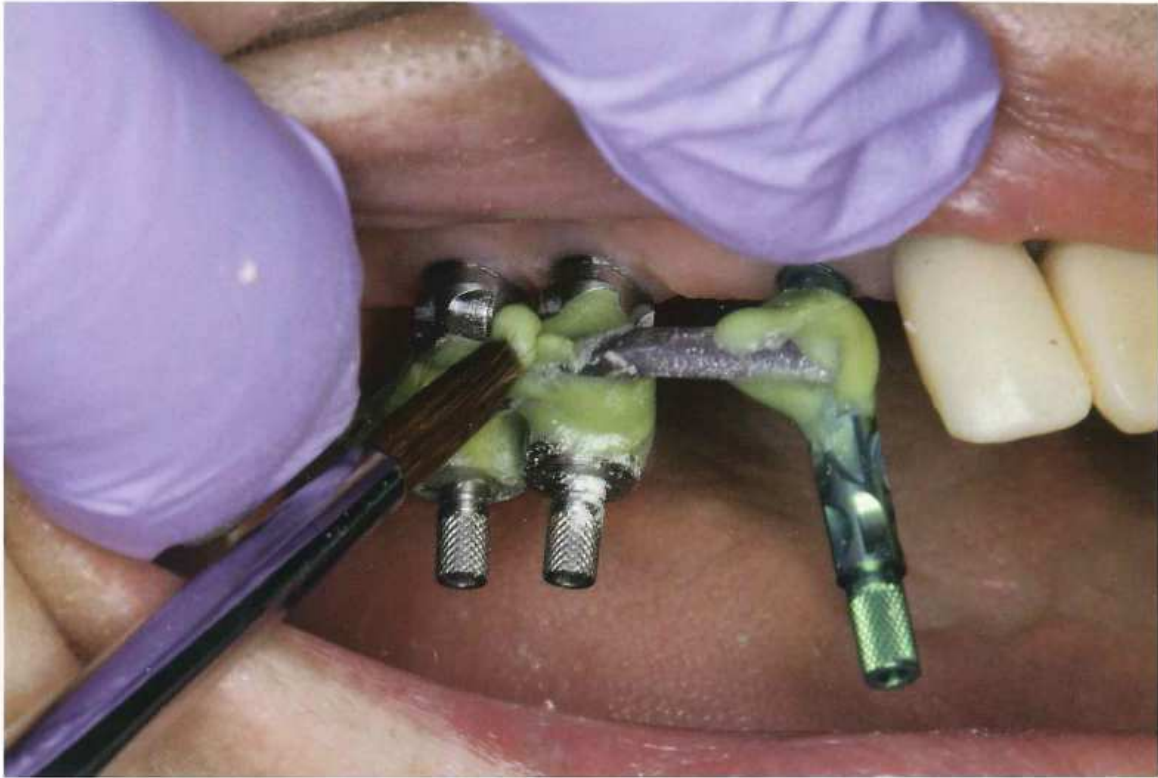下顎移動後



上下顎移動後

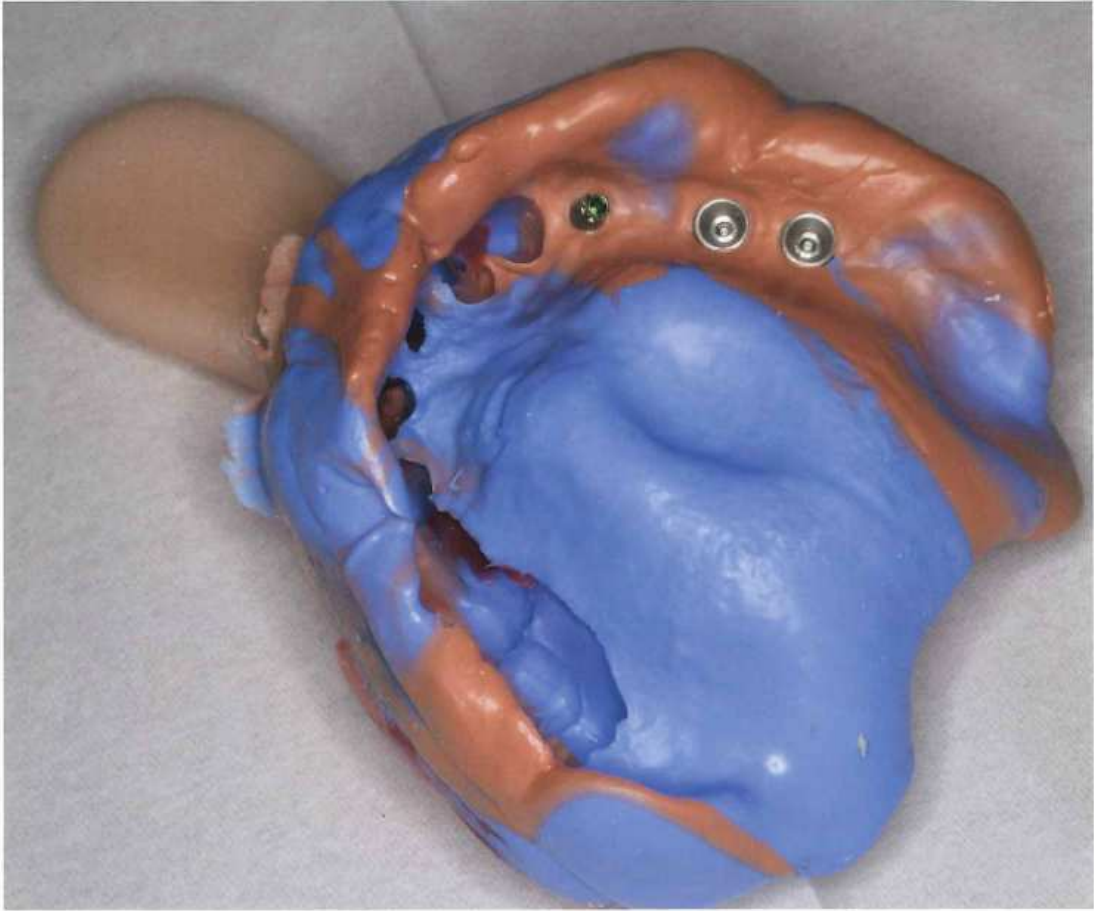


余 白

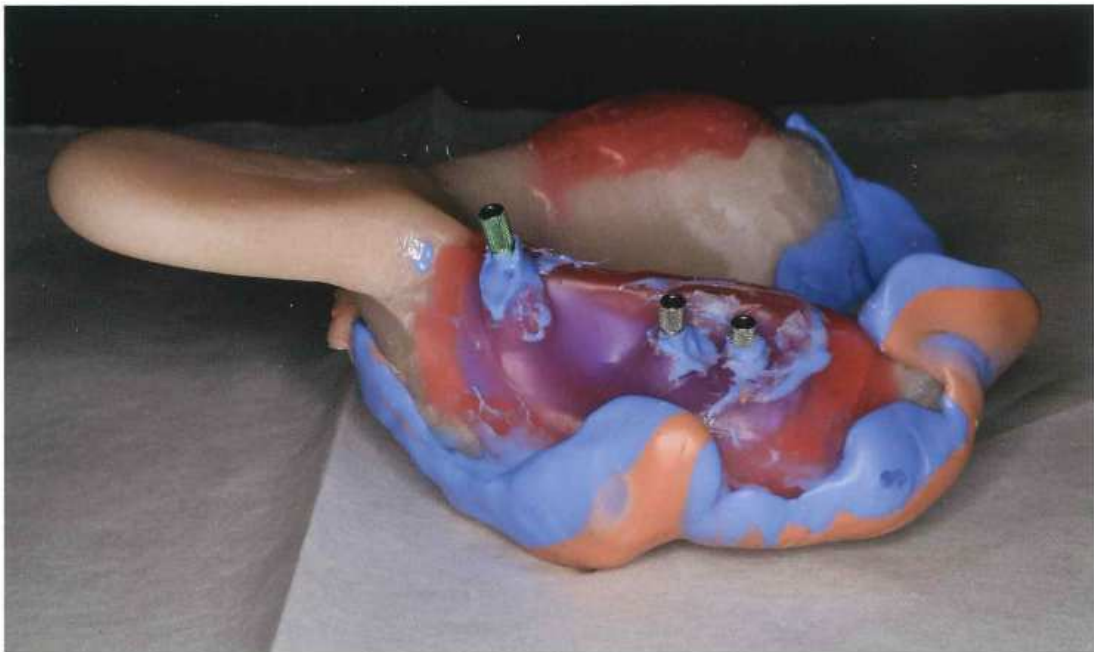


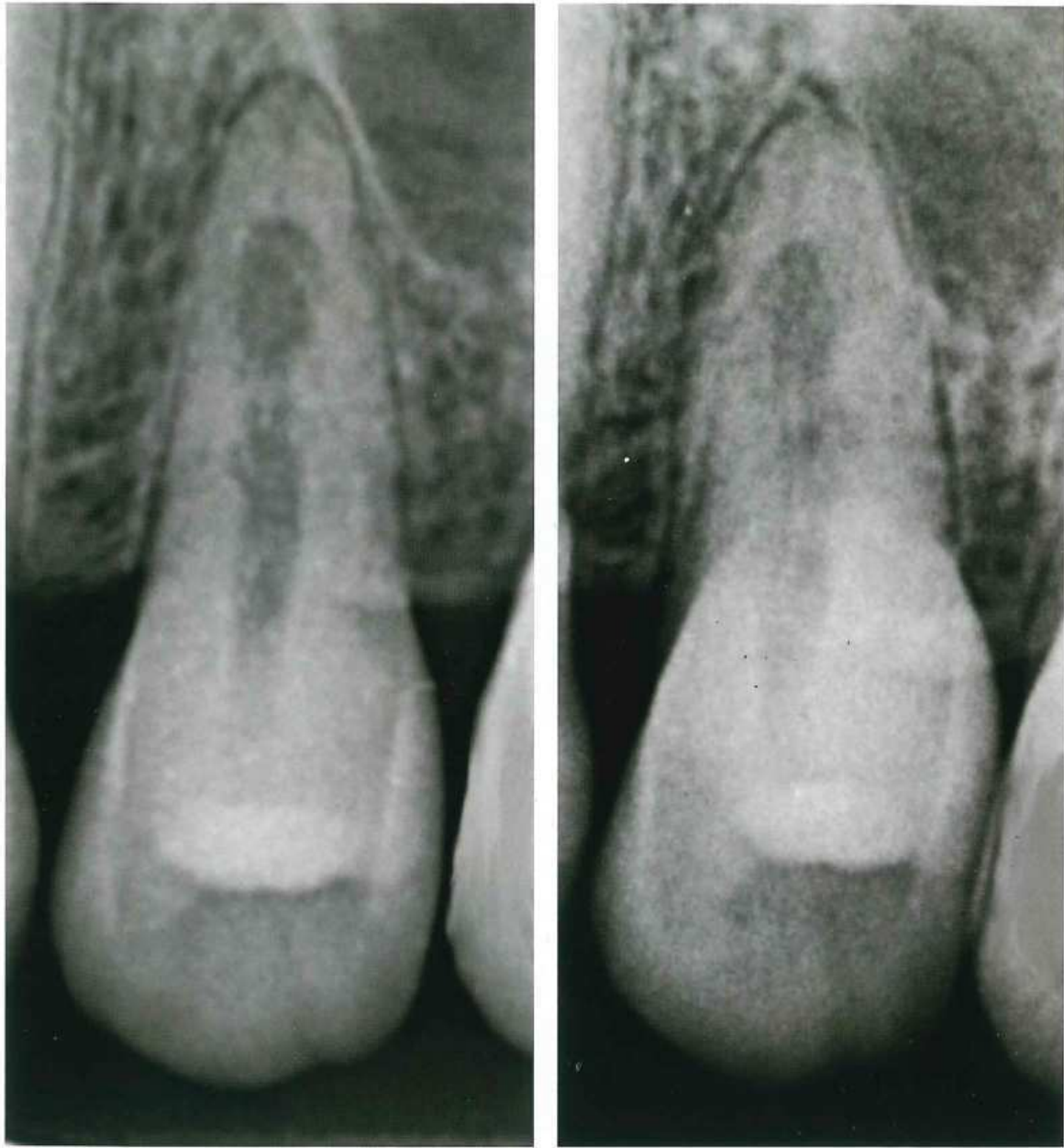

A



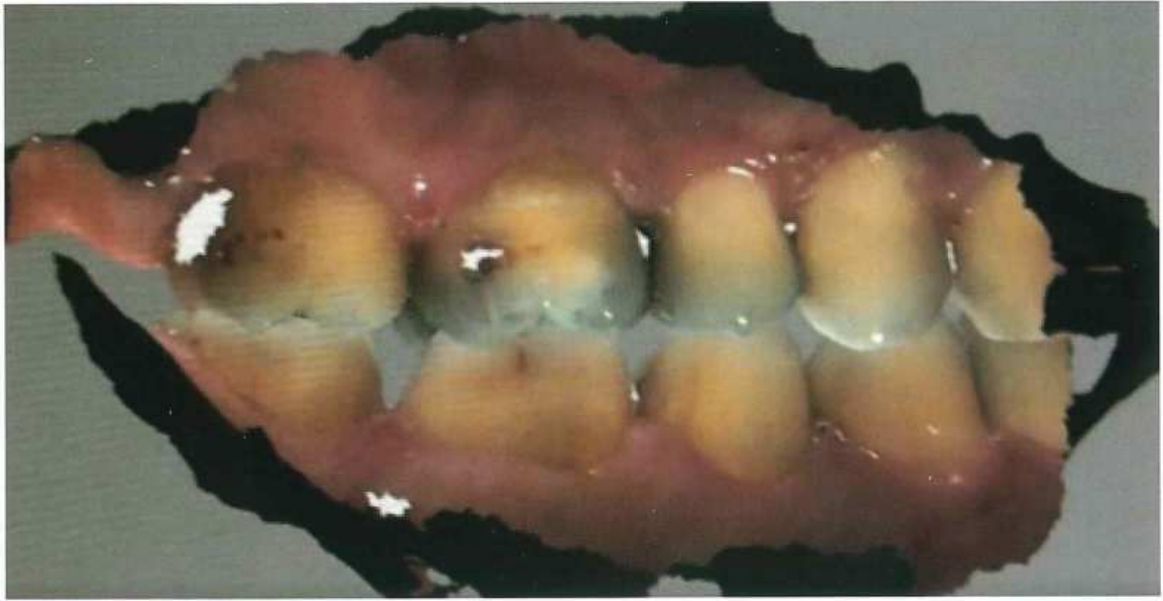B





No. 12

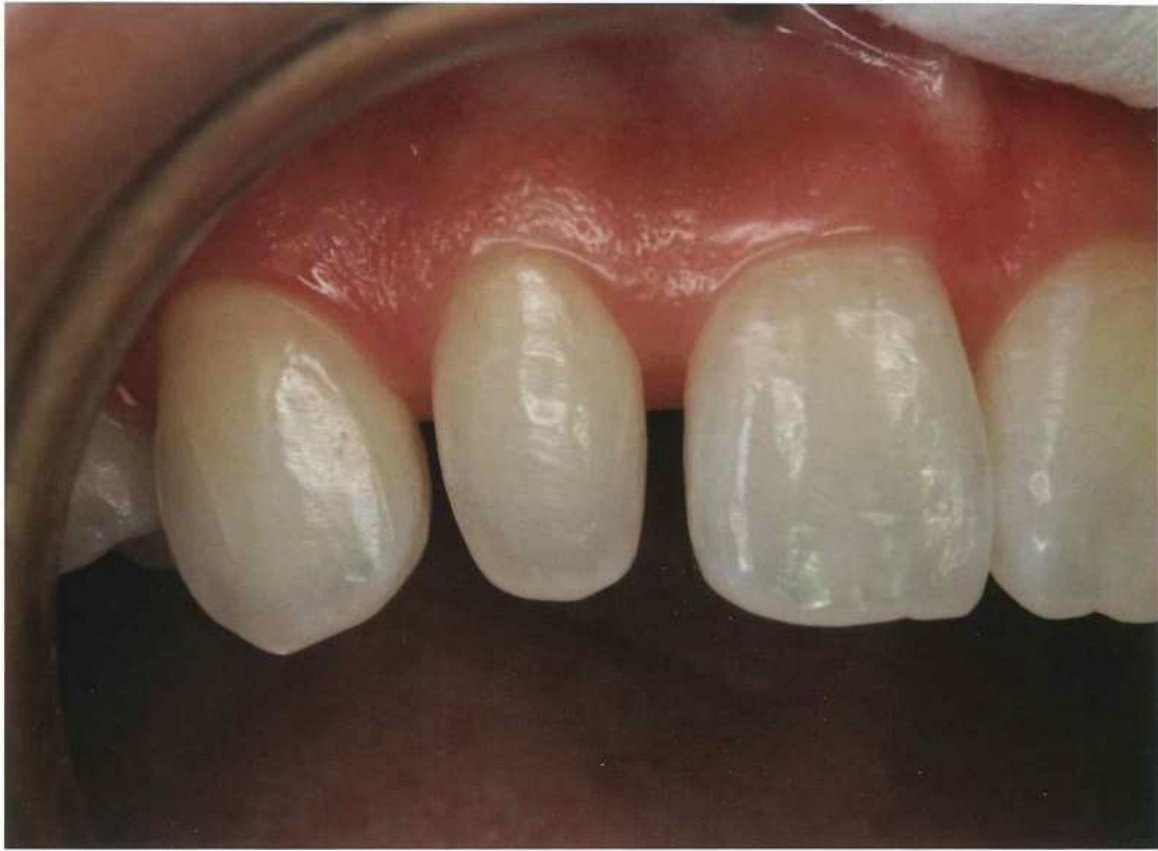(B 問題 36)



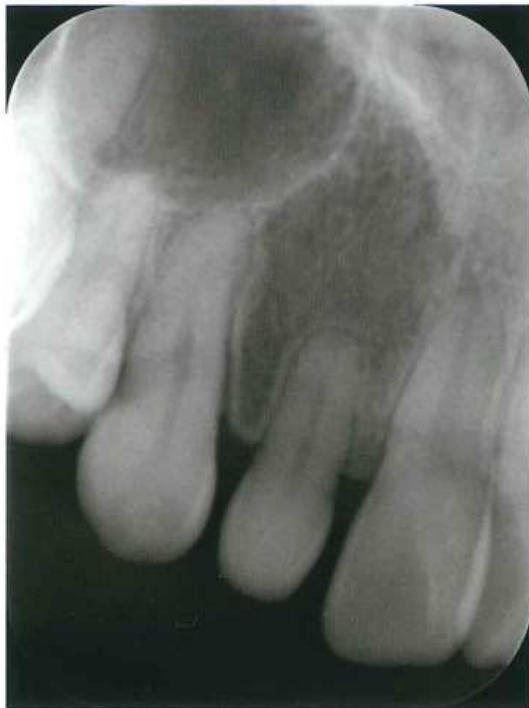No. 13

(B 問題 37)

A



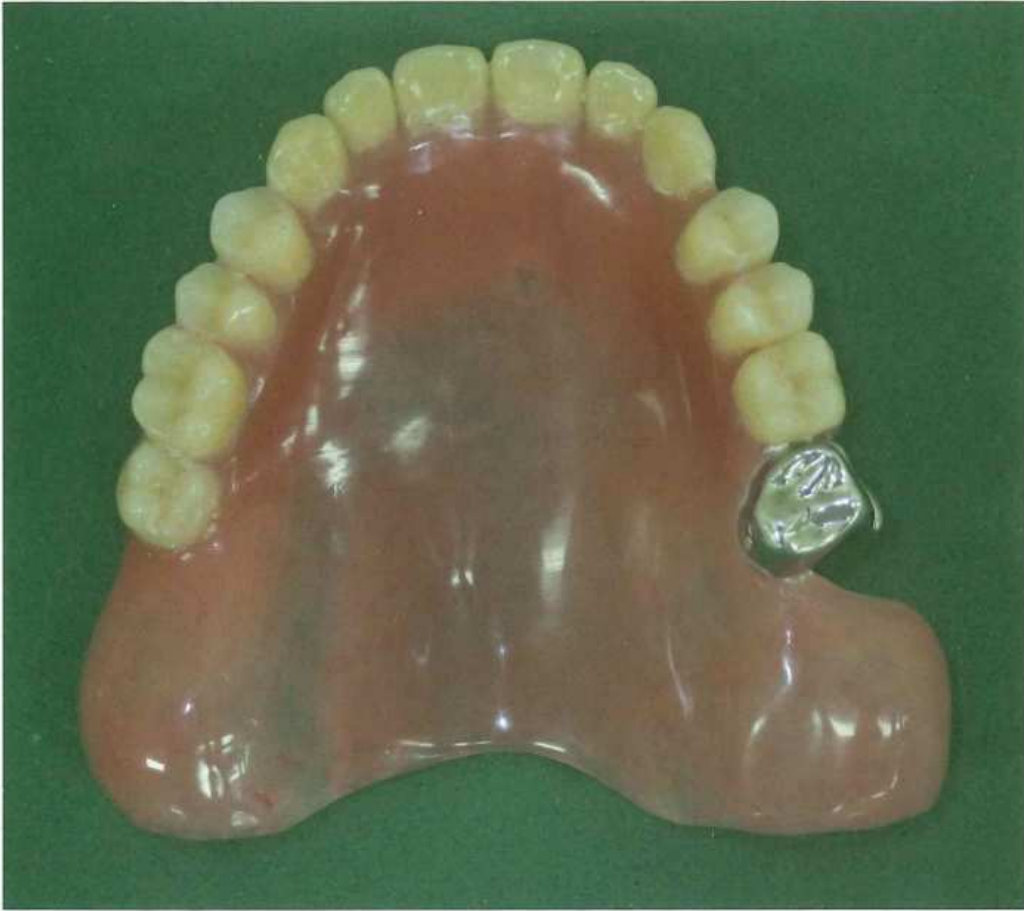B



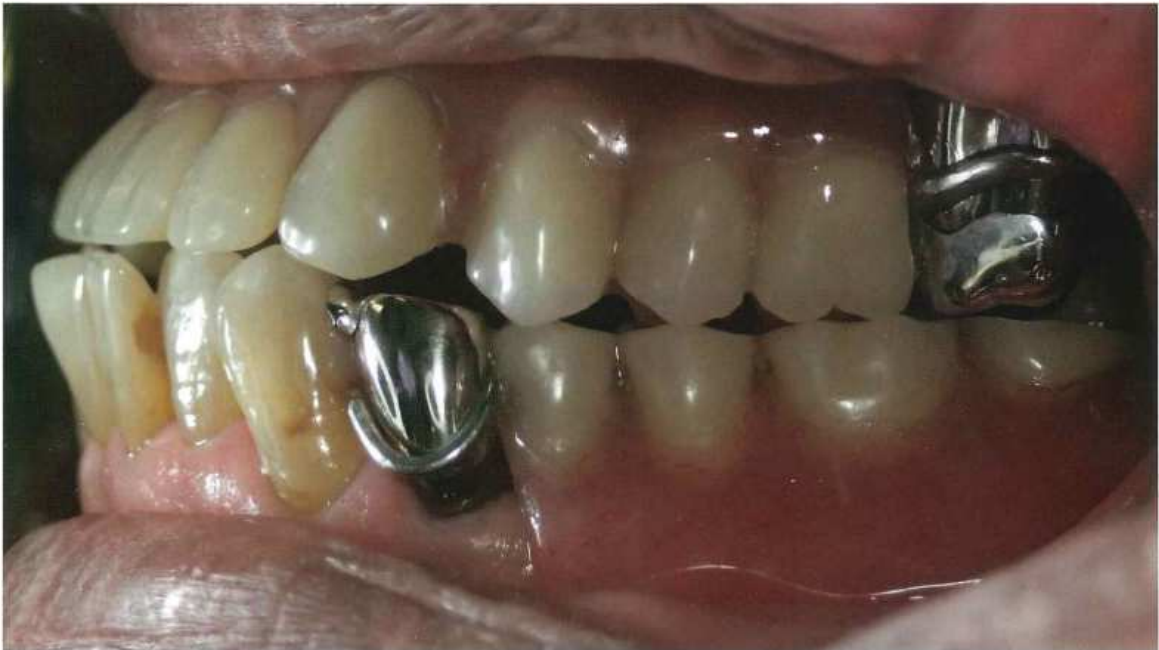No. 14

(B 問題 38)

A



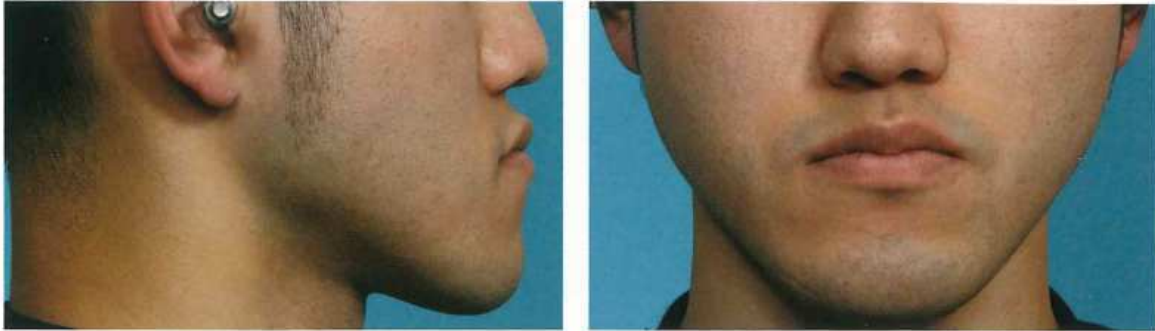
B



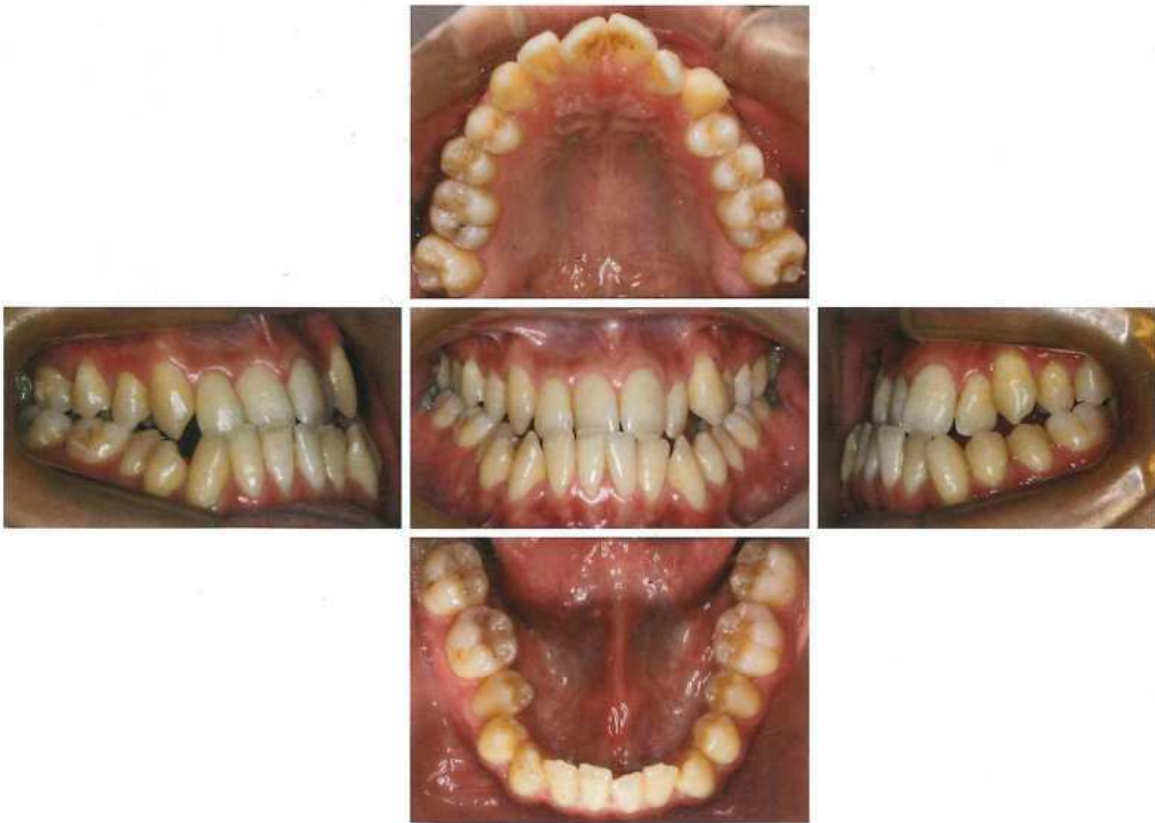No. 15

(B 問題 42)

A



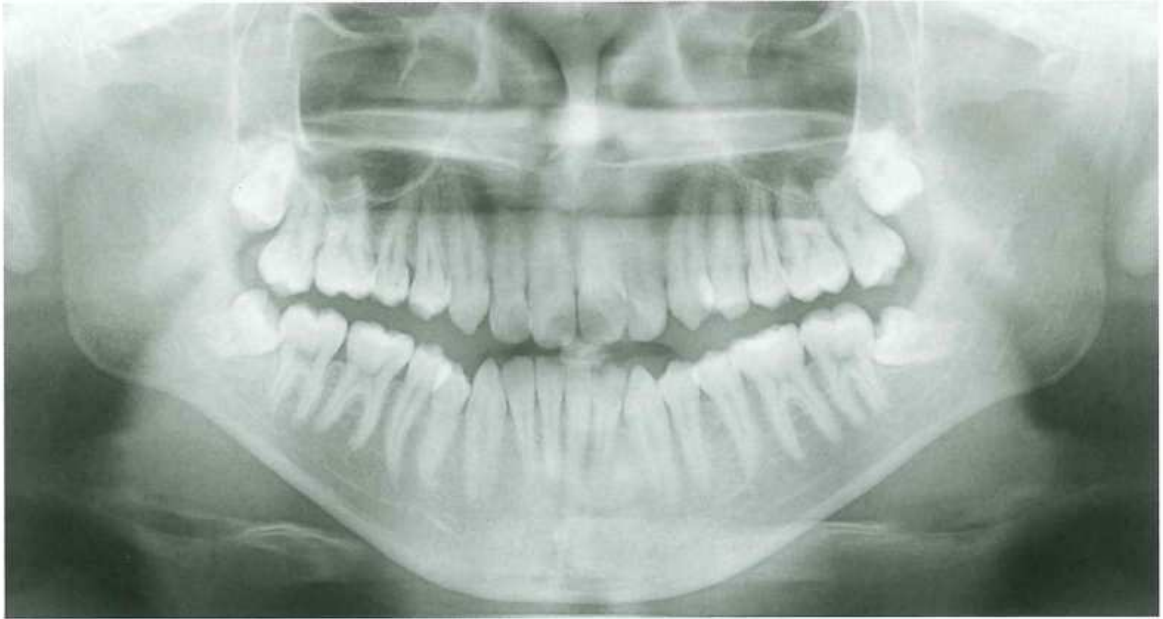B

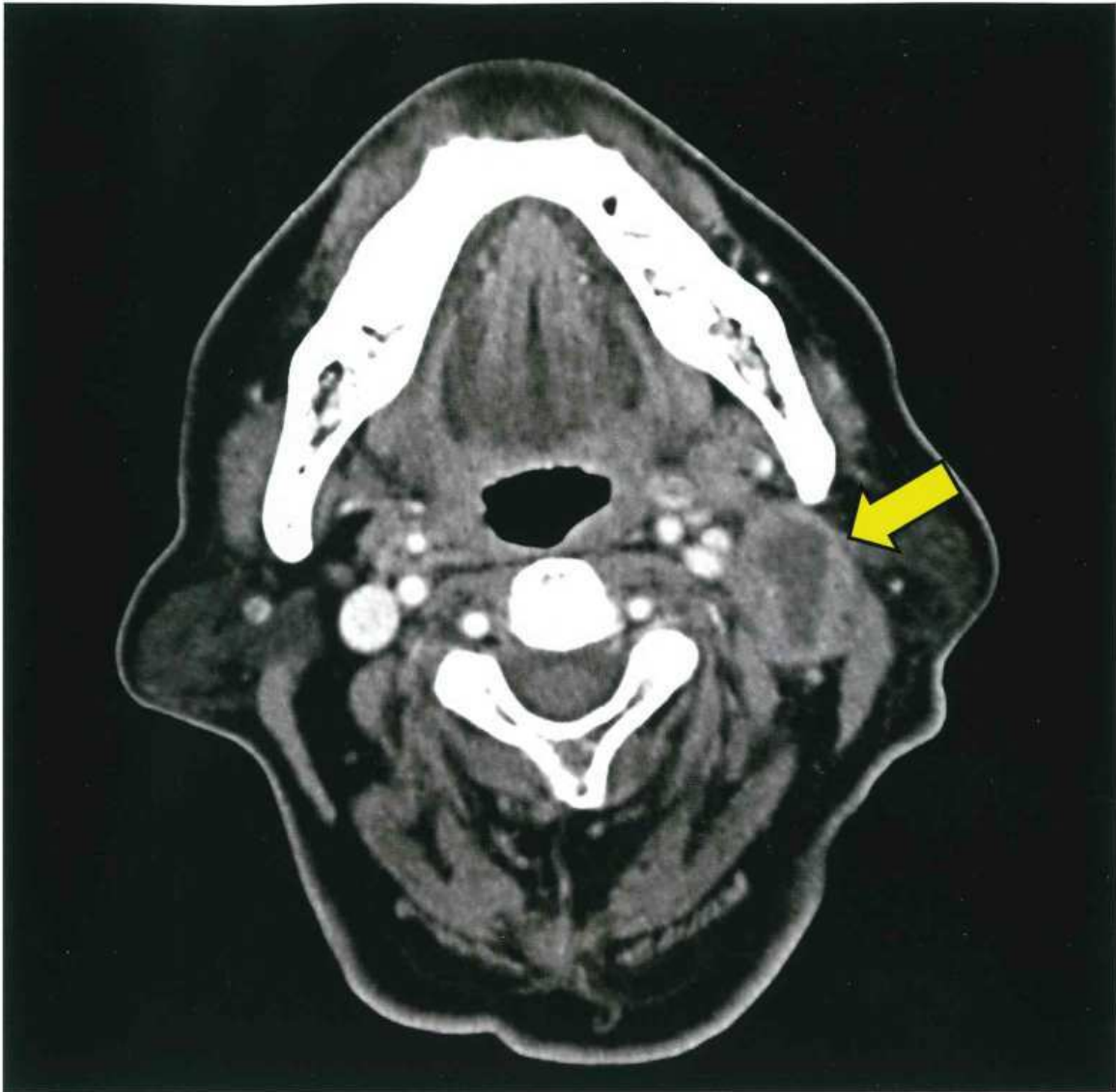

No. 15

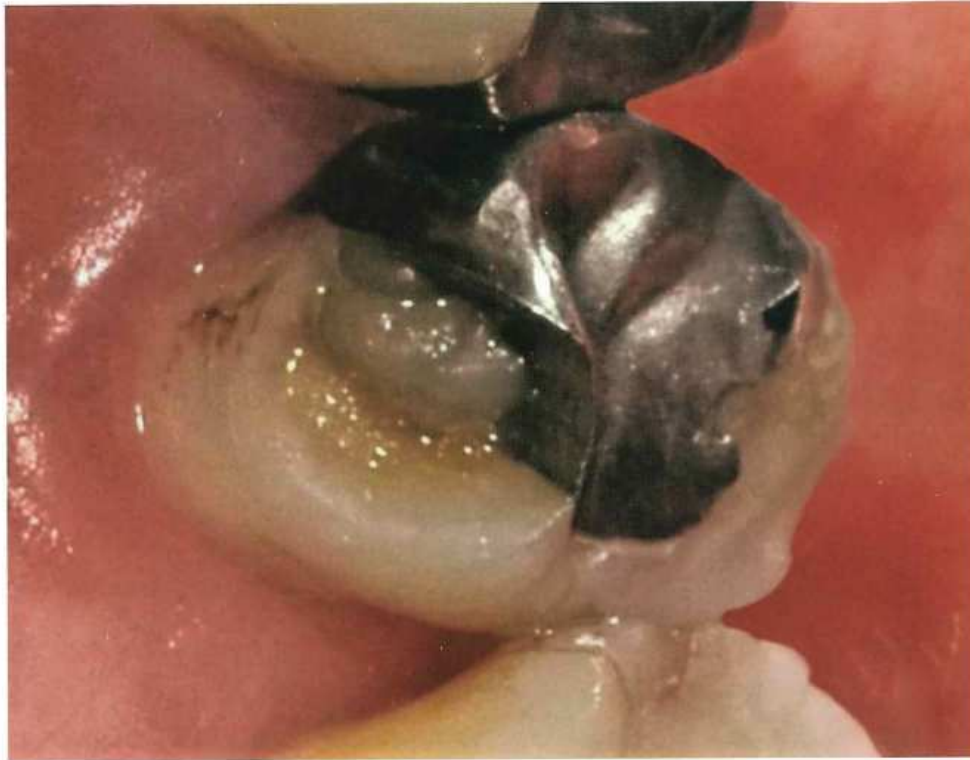(B 問題 42)

C

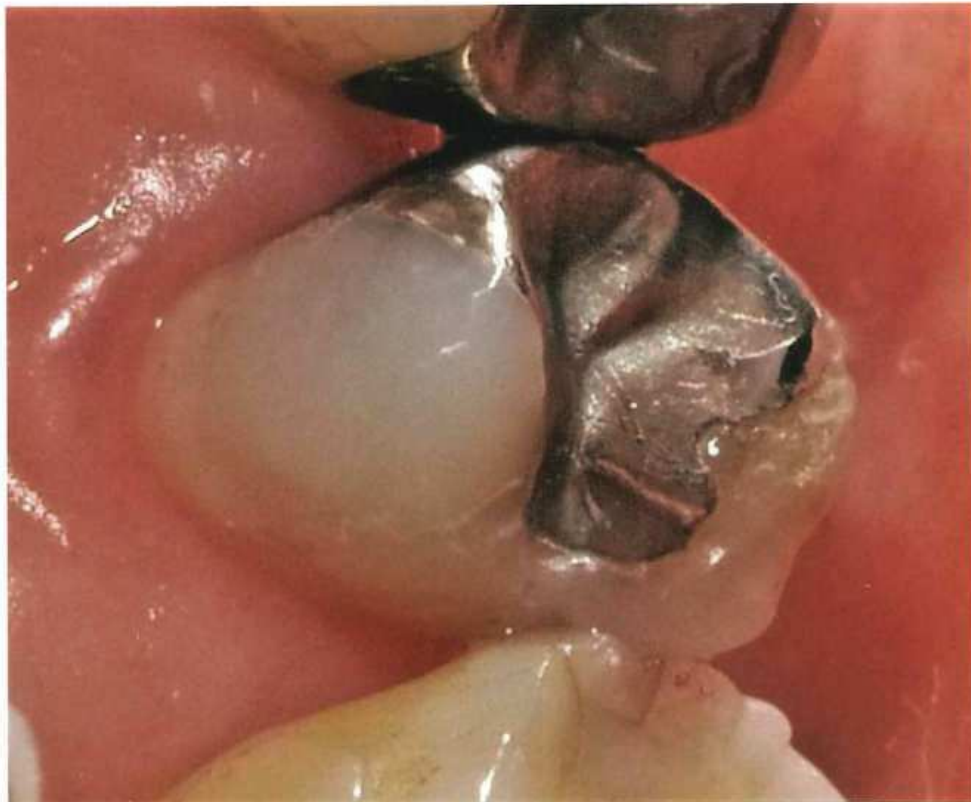







術前



術後

No. 18

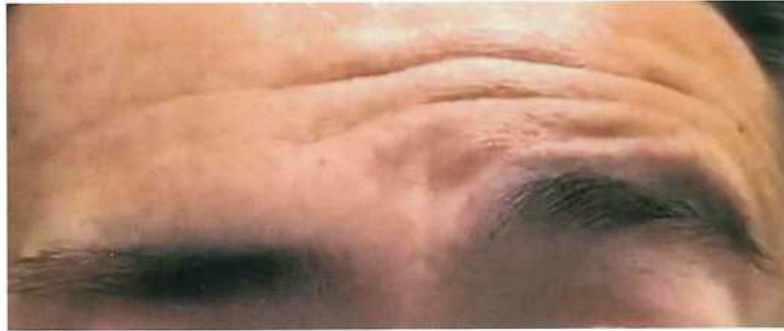(B 問題 45)



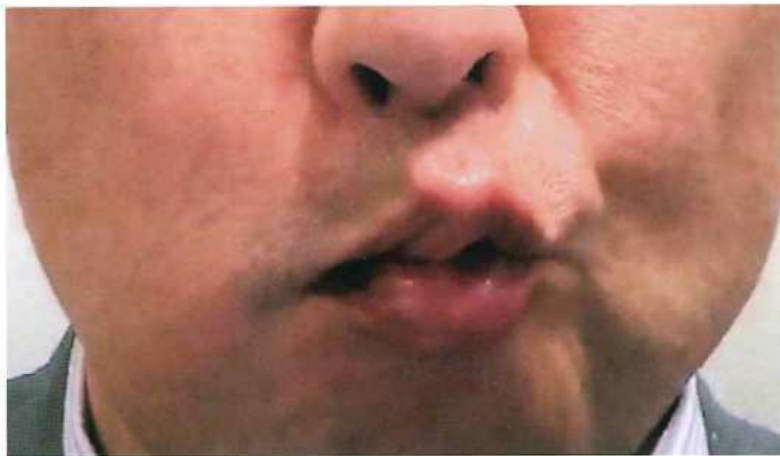No. 19

(B 問題 47)

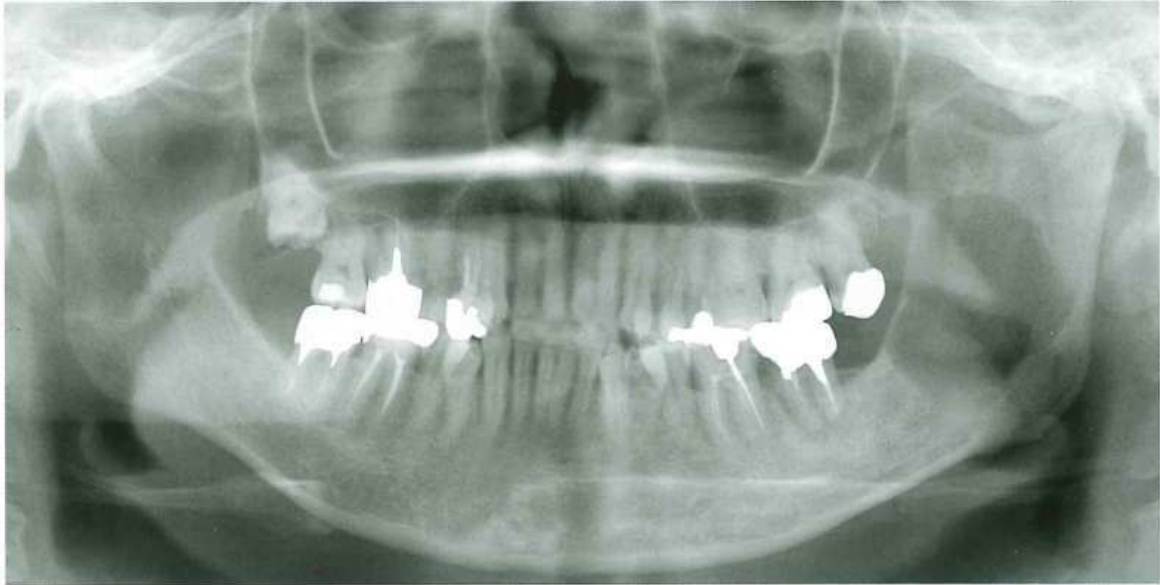
A



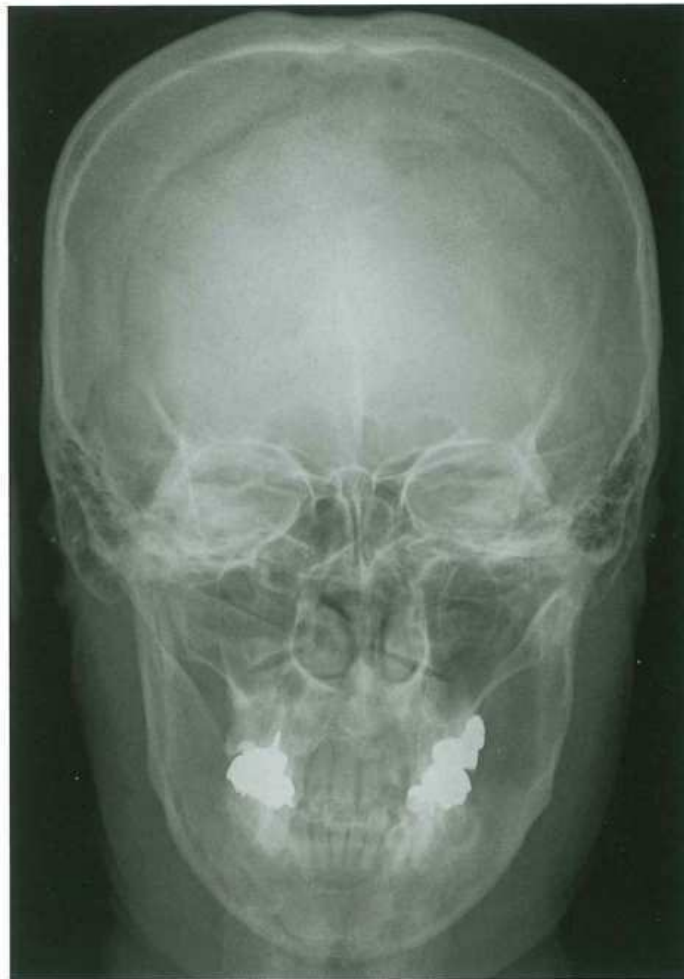B



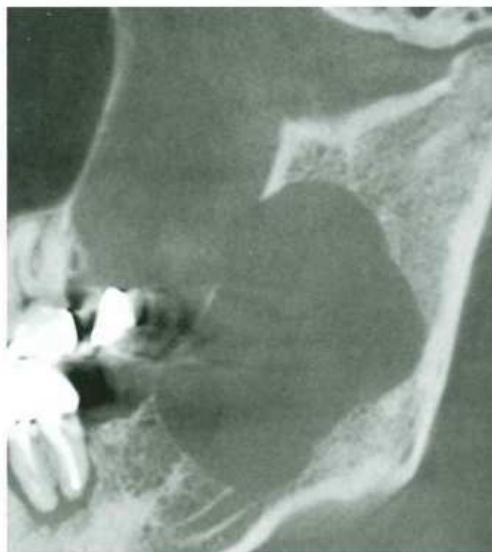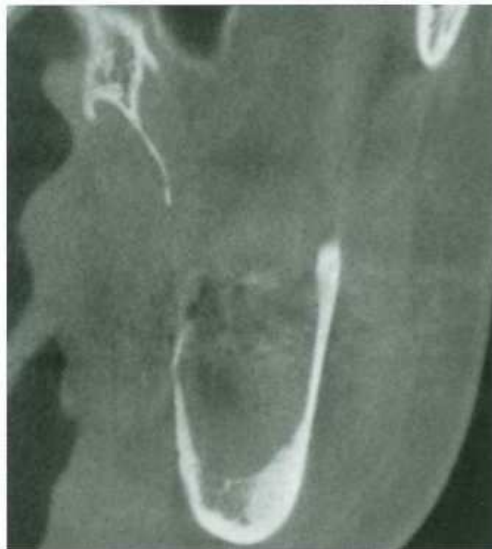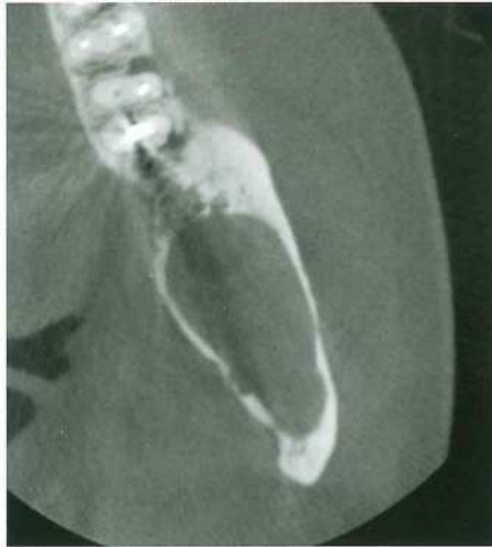A



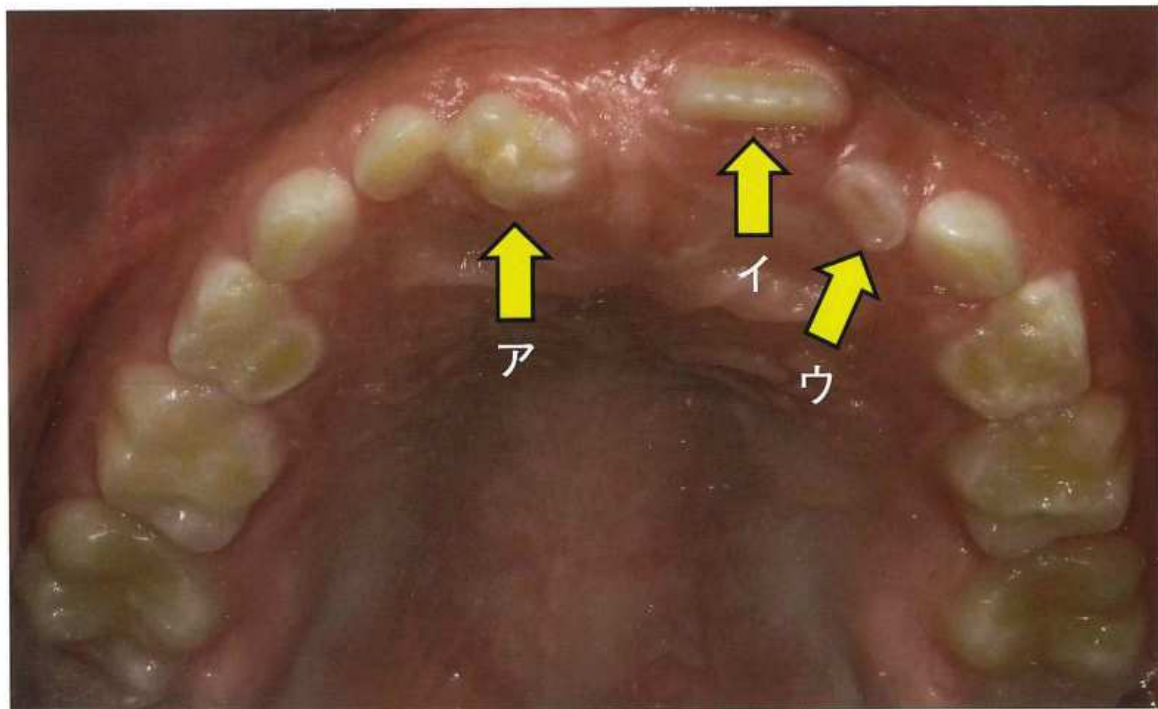
B



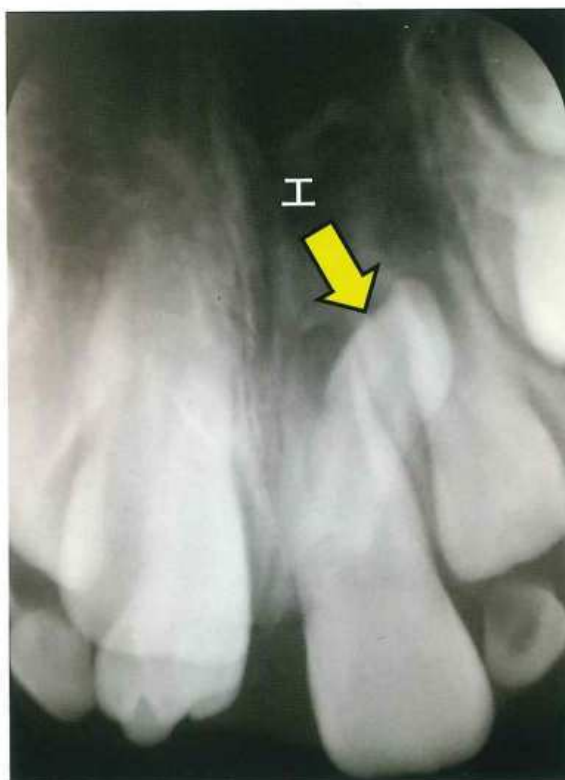C



A



B

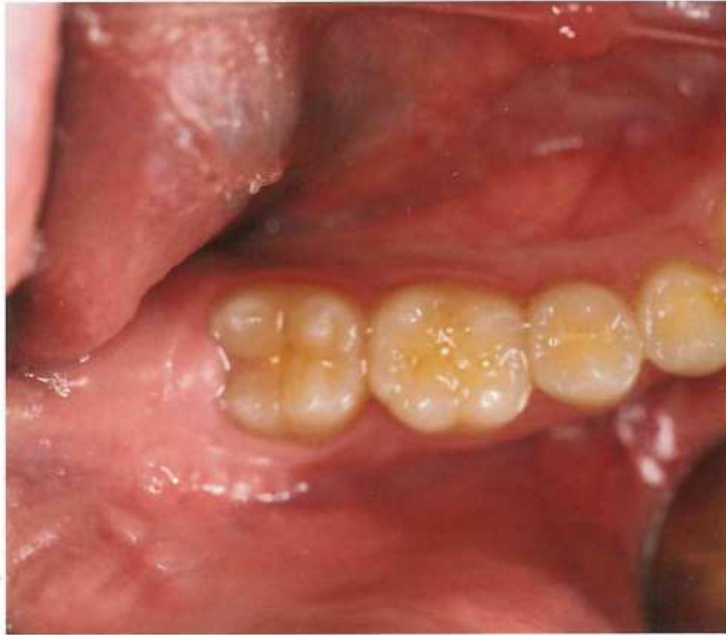

余 白

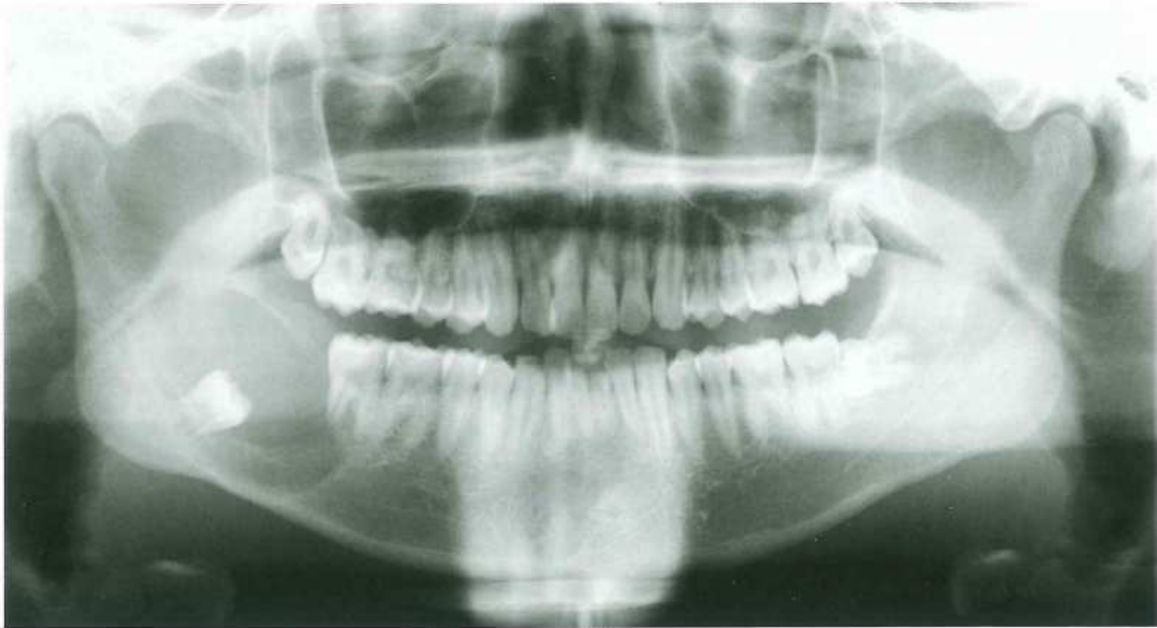No. 22

(B 問題 51)

A

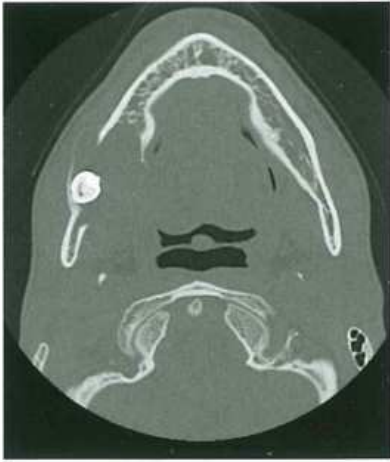

B

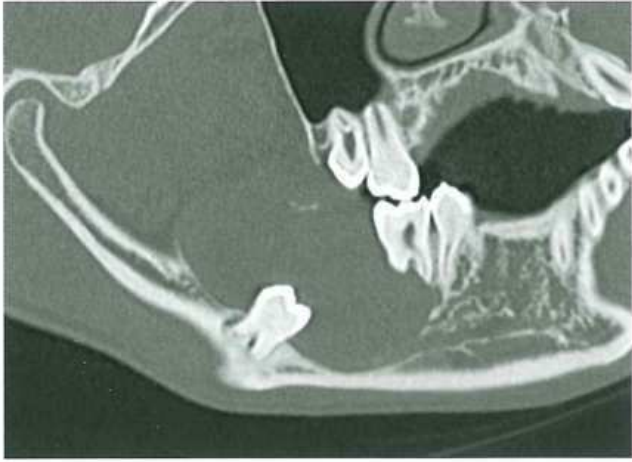



C

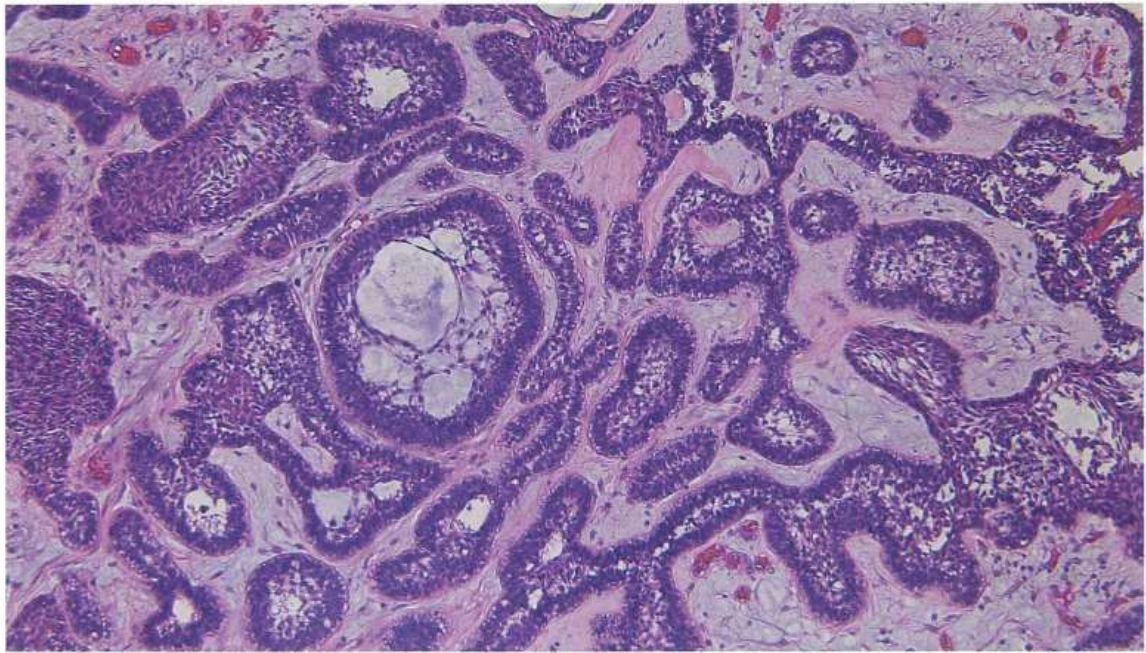


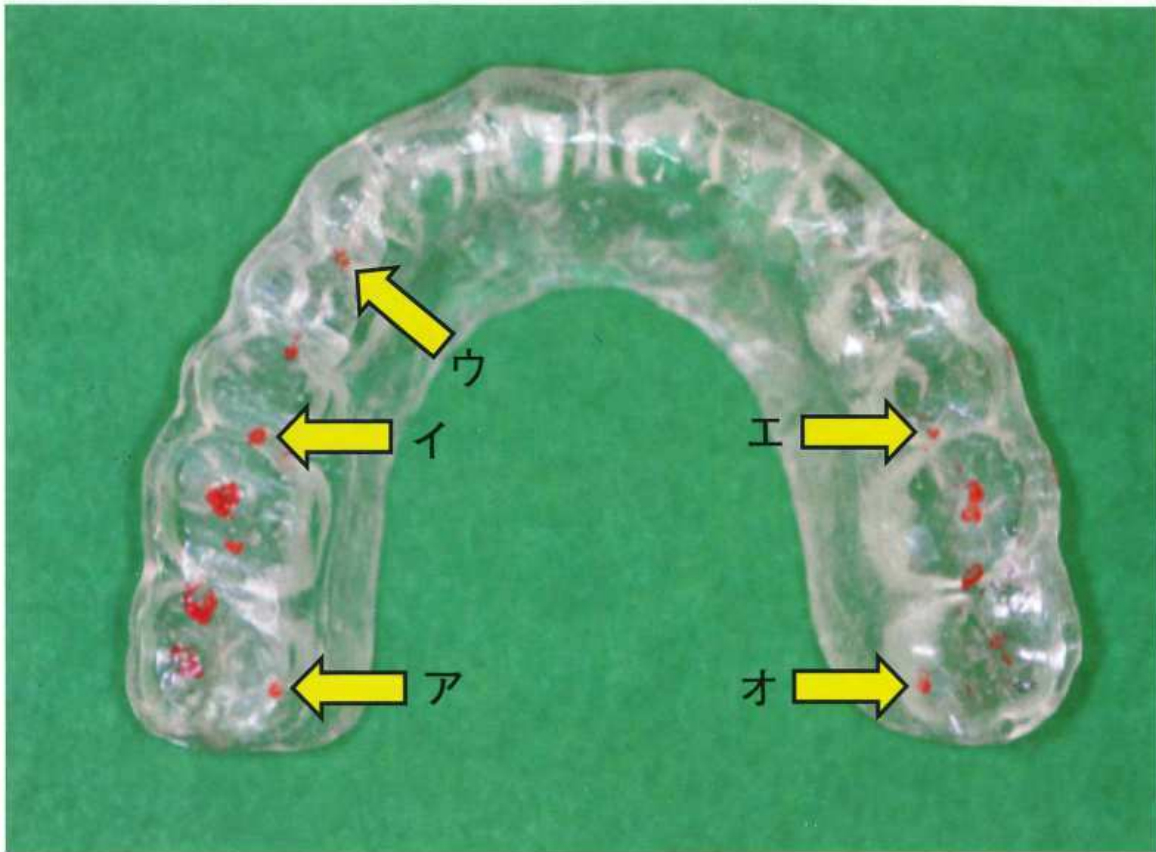
横断像



矢状断像

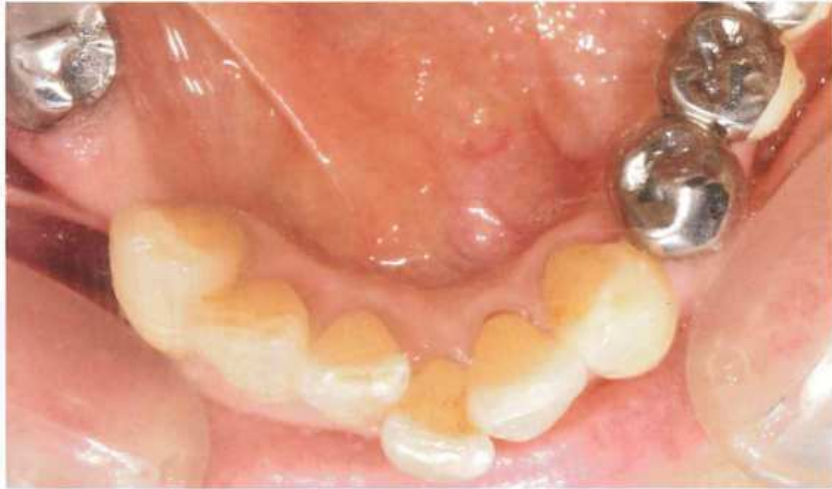D



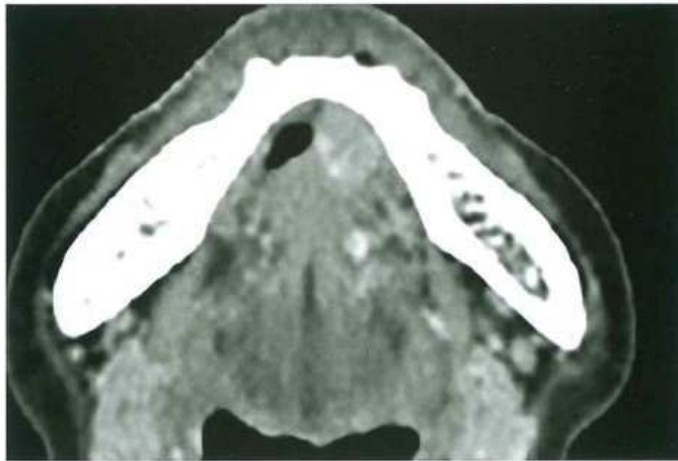


余 白

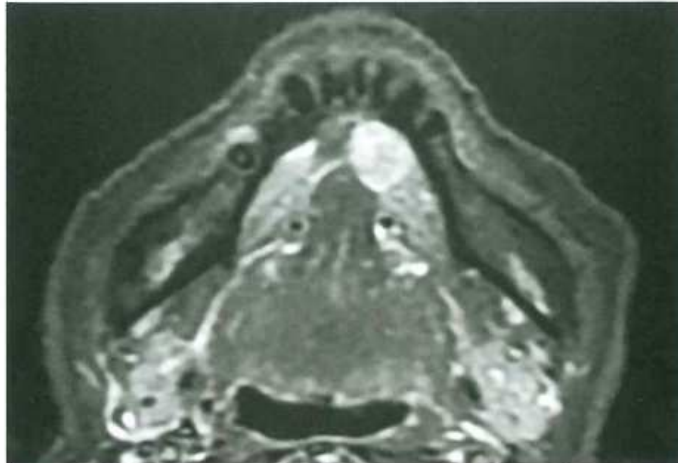
A



B



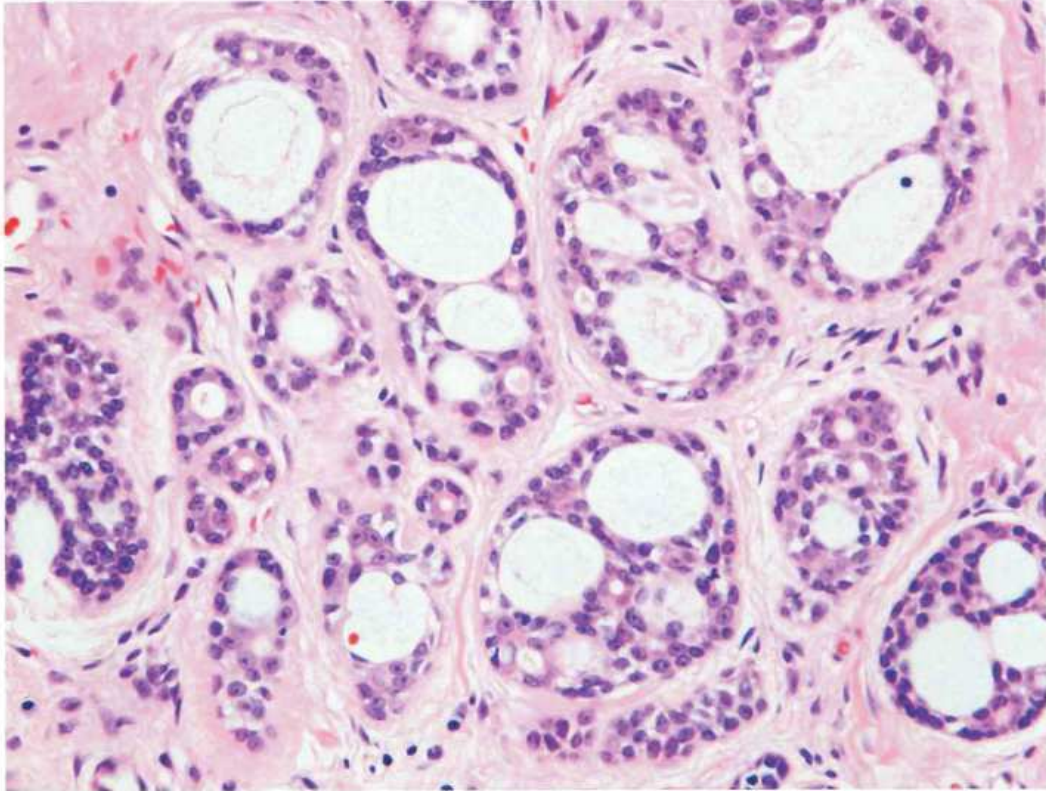
C



No. 24

(B 問題 54)

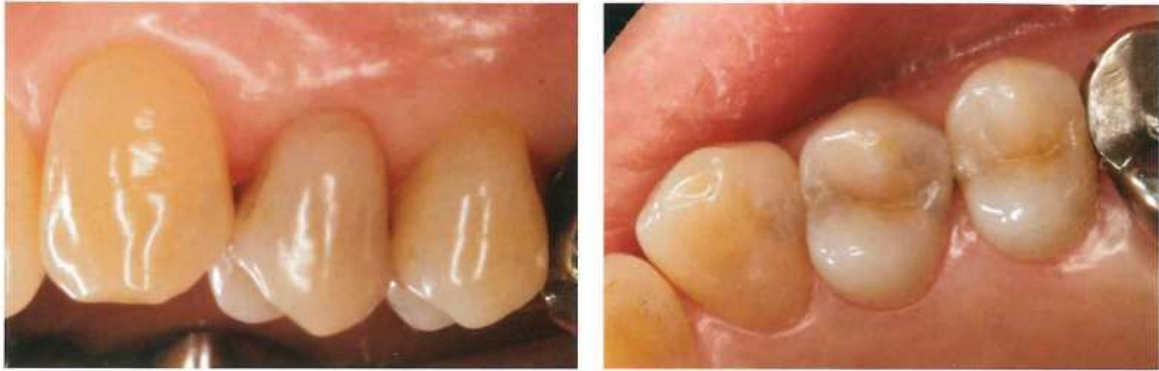D



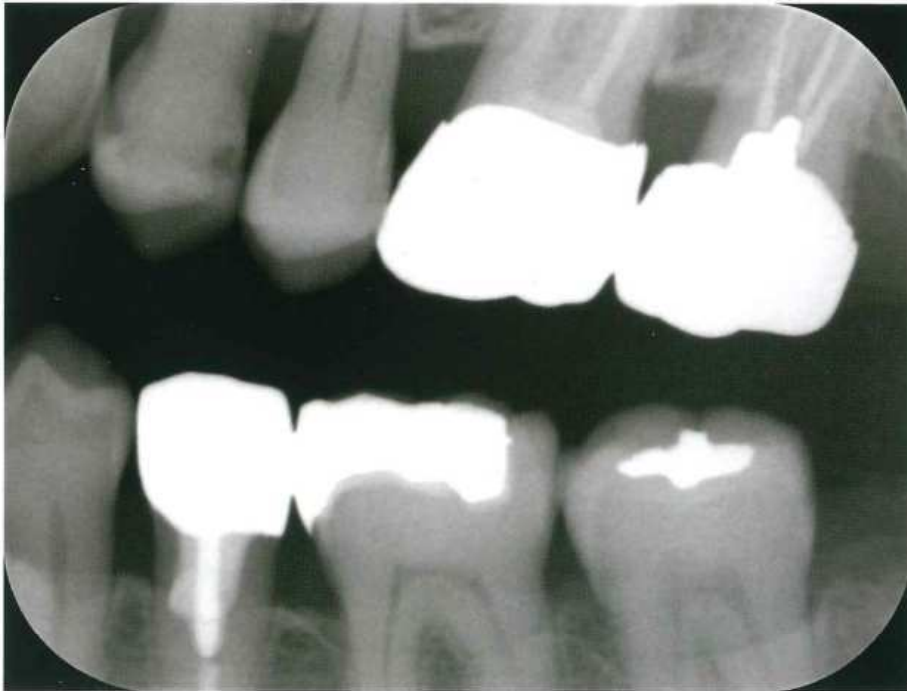No. 25

(B 問題 58)

A



B

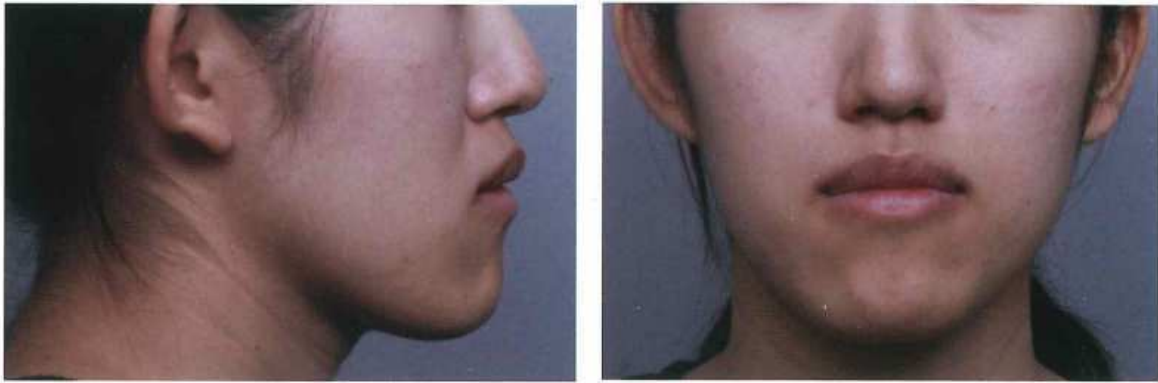

余 白

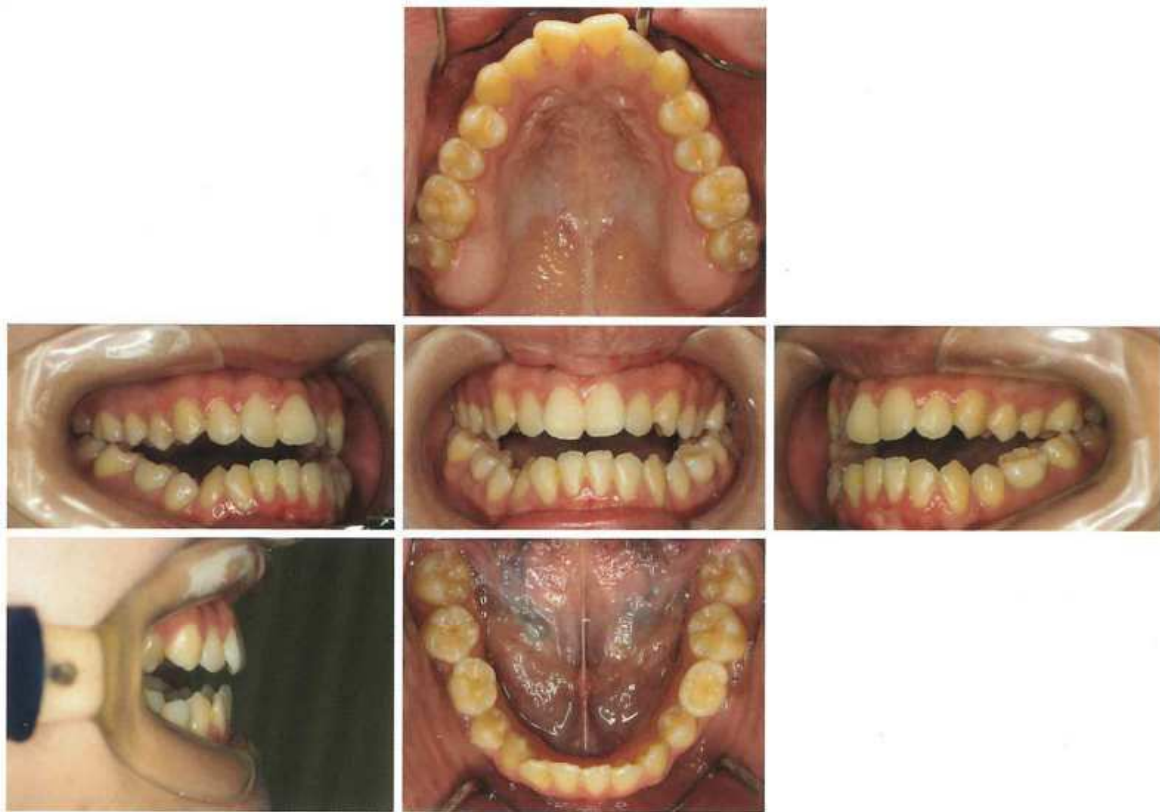No. 26

(B 問題 59)

A



B

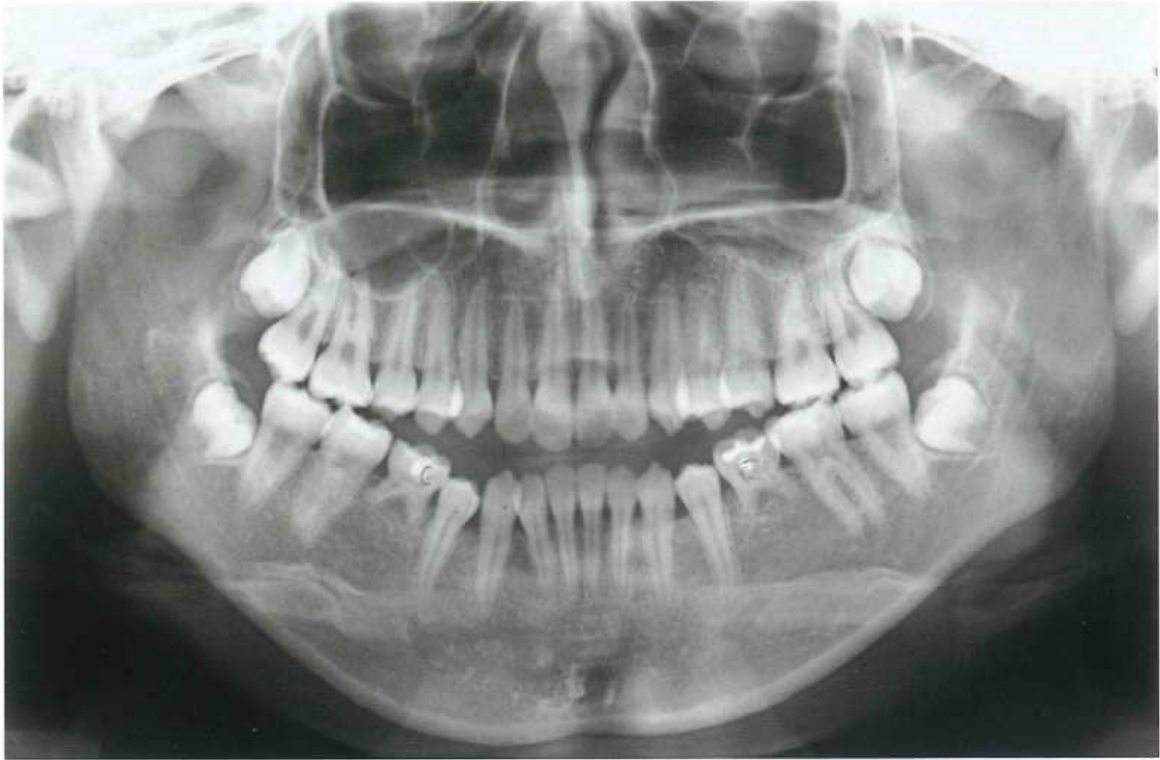




No. 26

(B 問題 59)

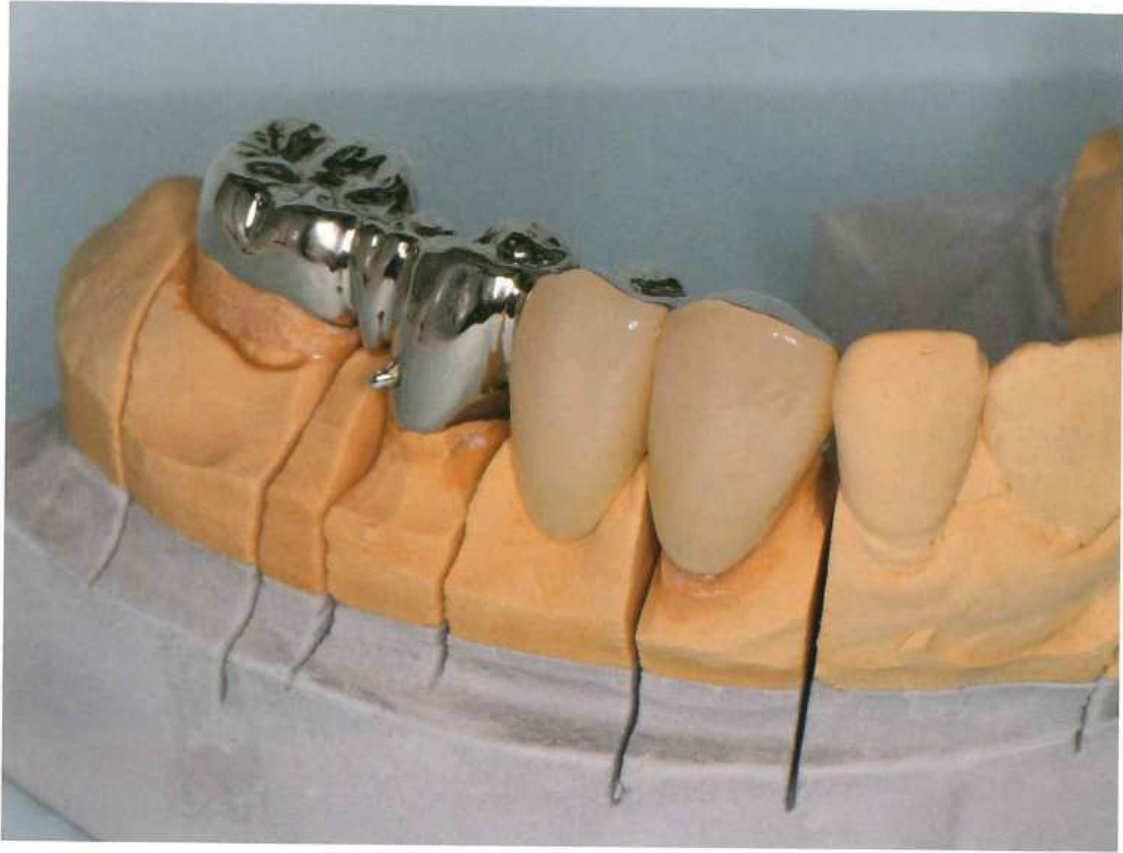C



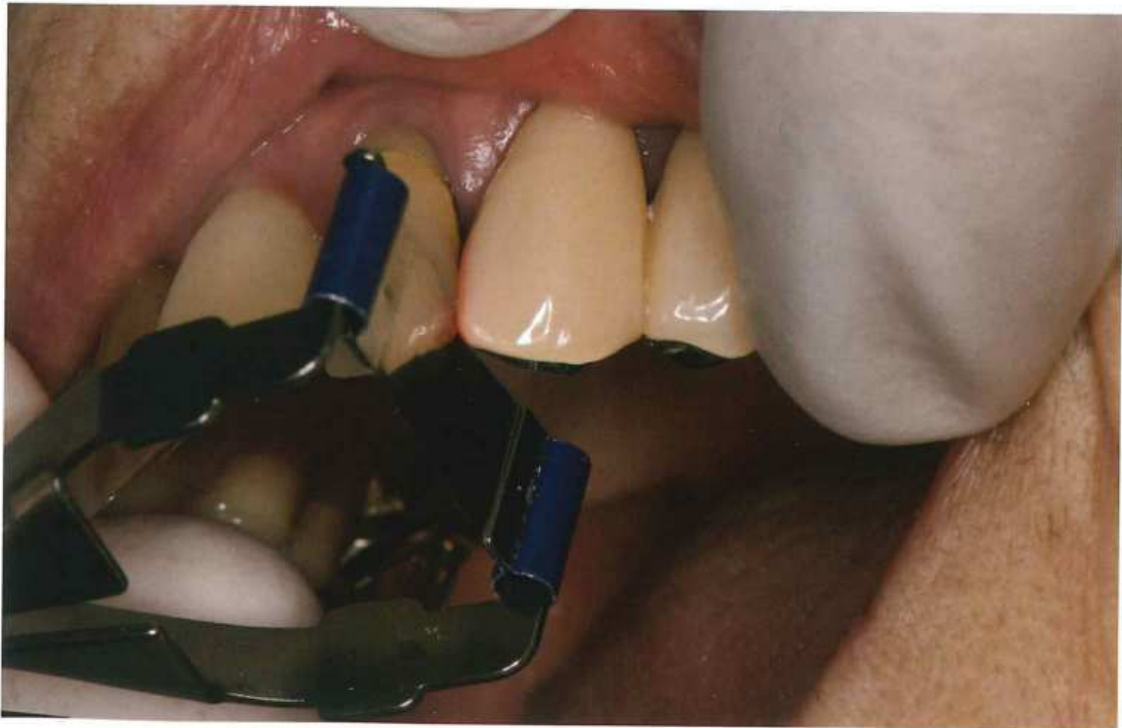No. 27

(B 問題 60)

A

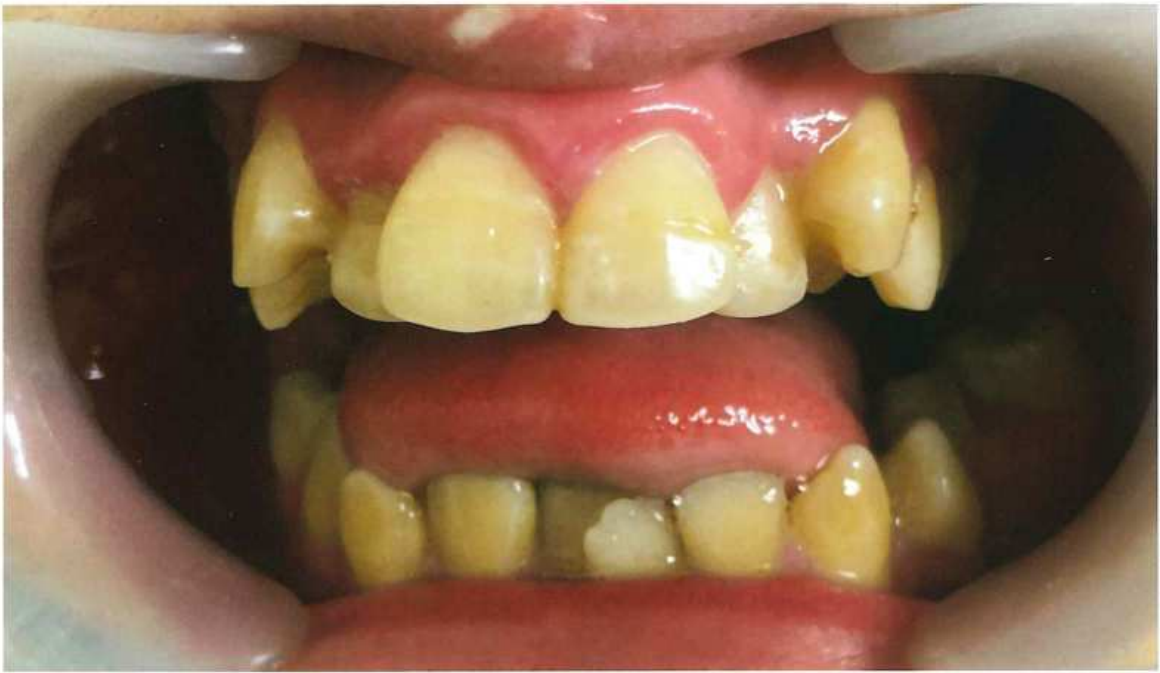

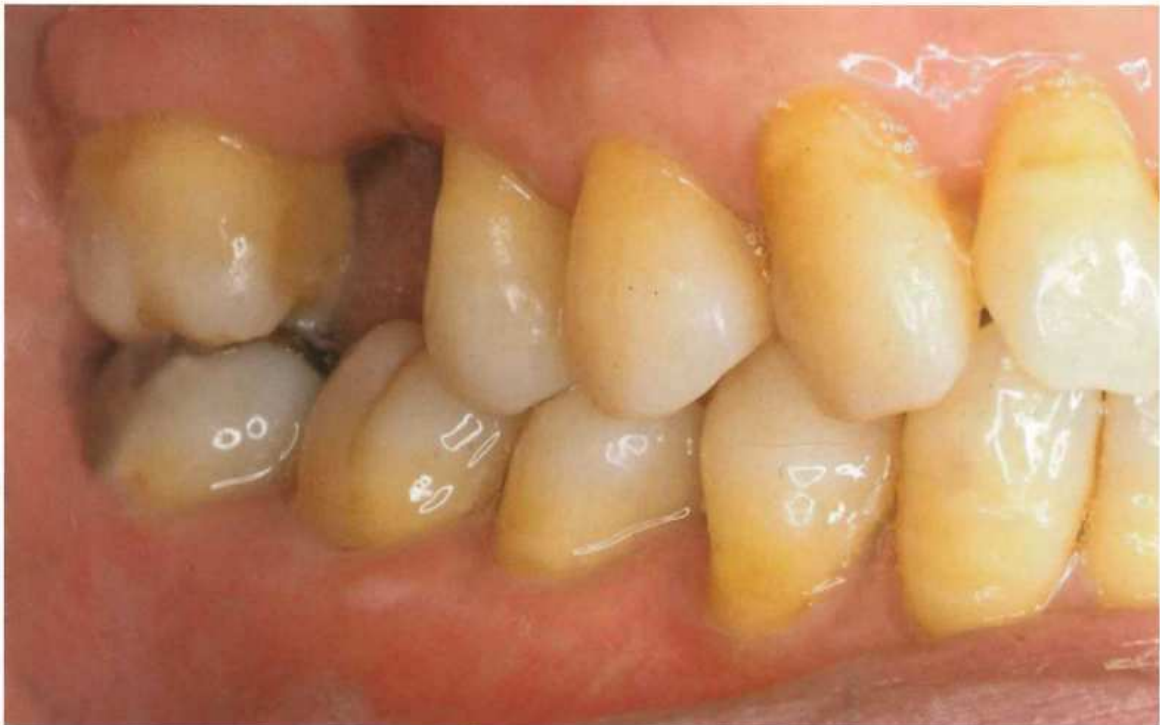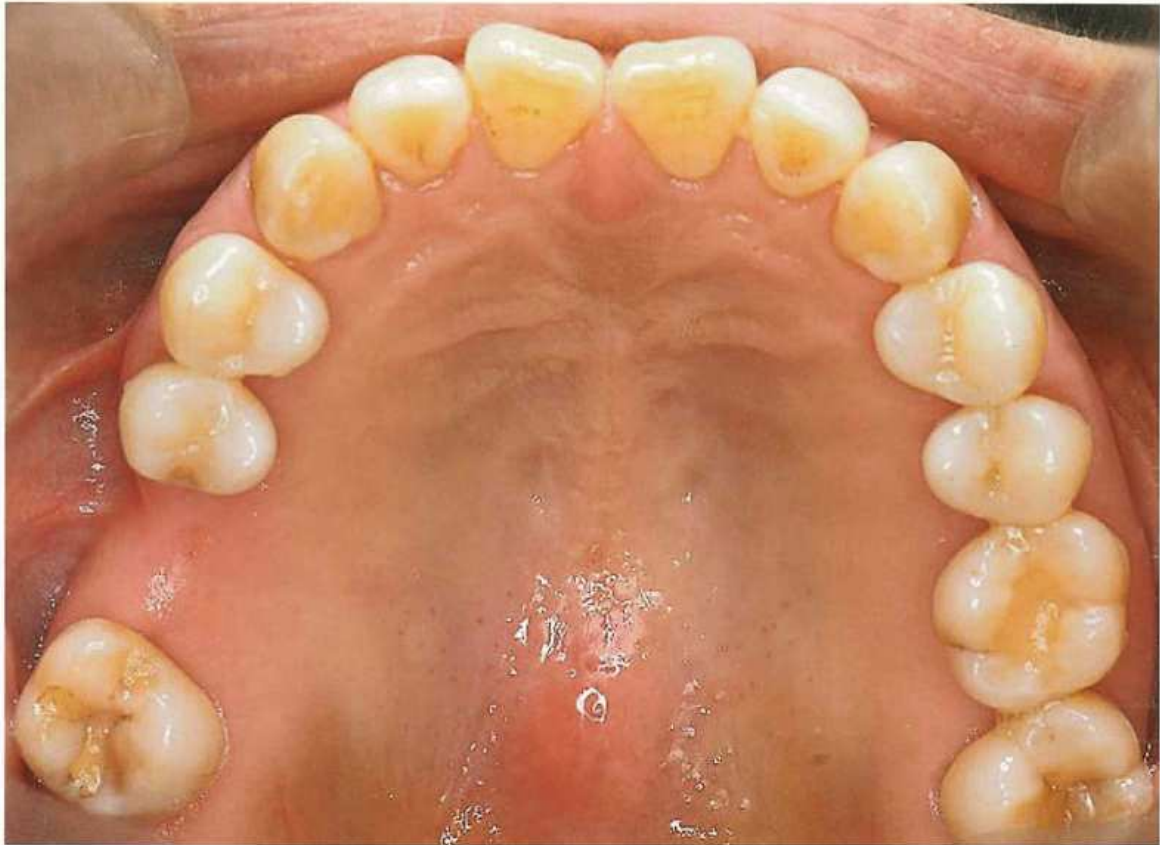B



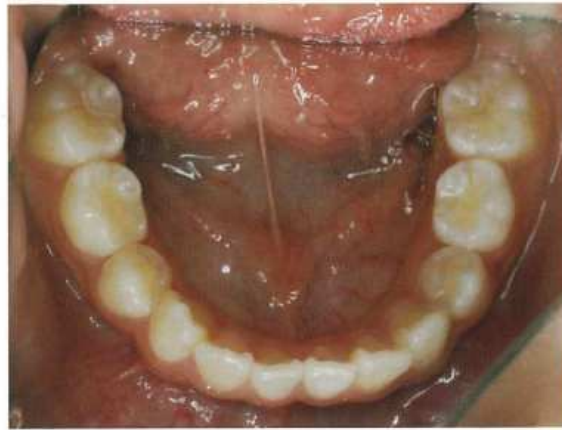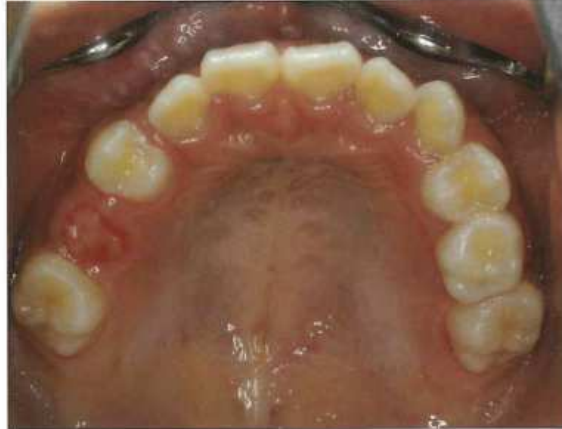No. 28

(B 問題 61)

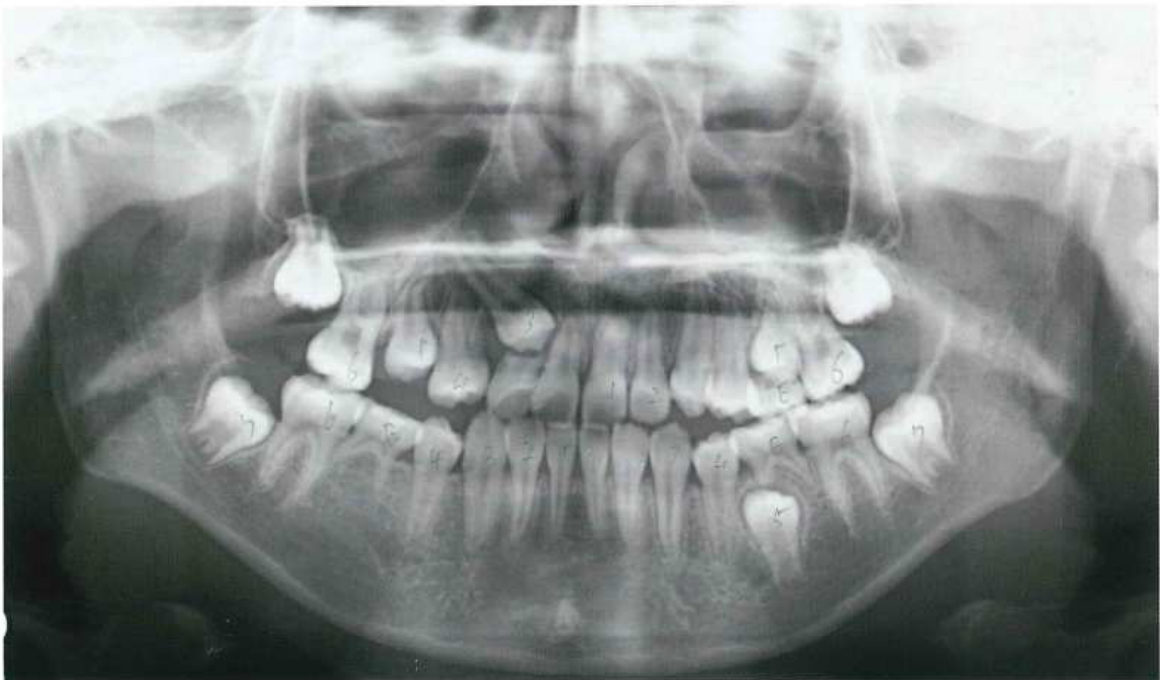



A



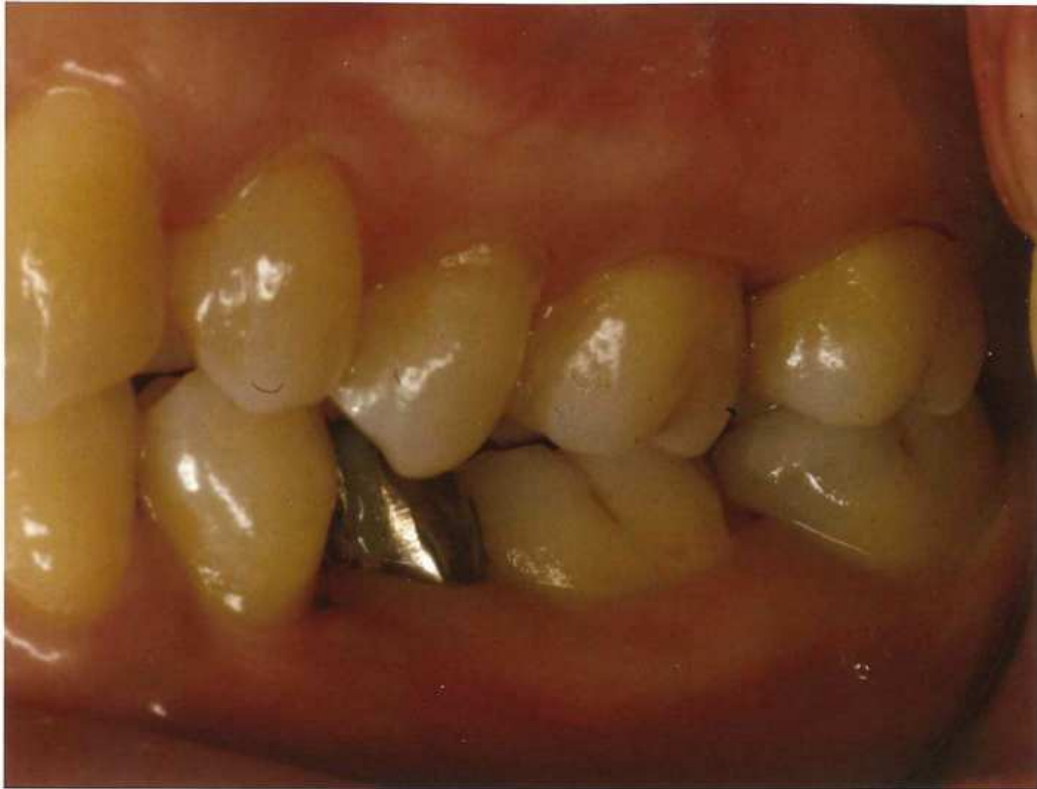B



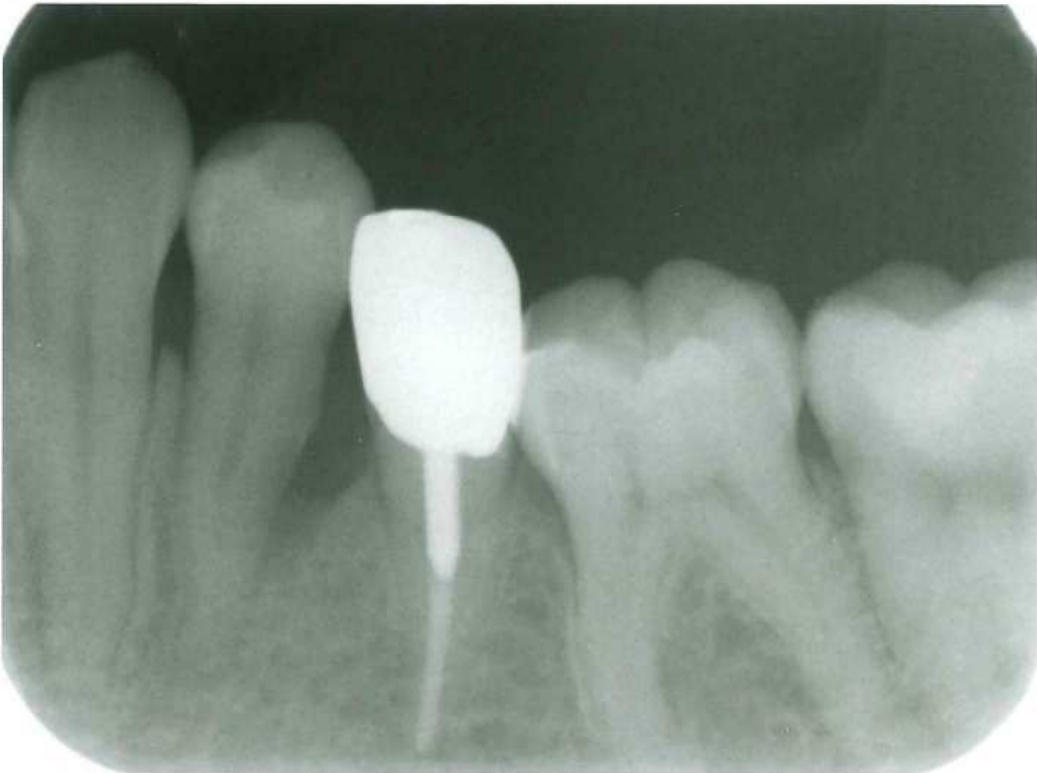
No. 31

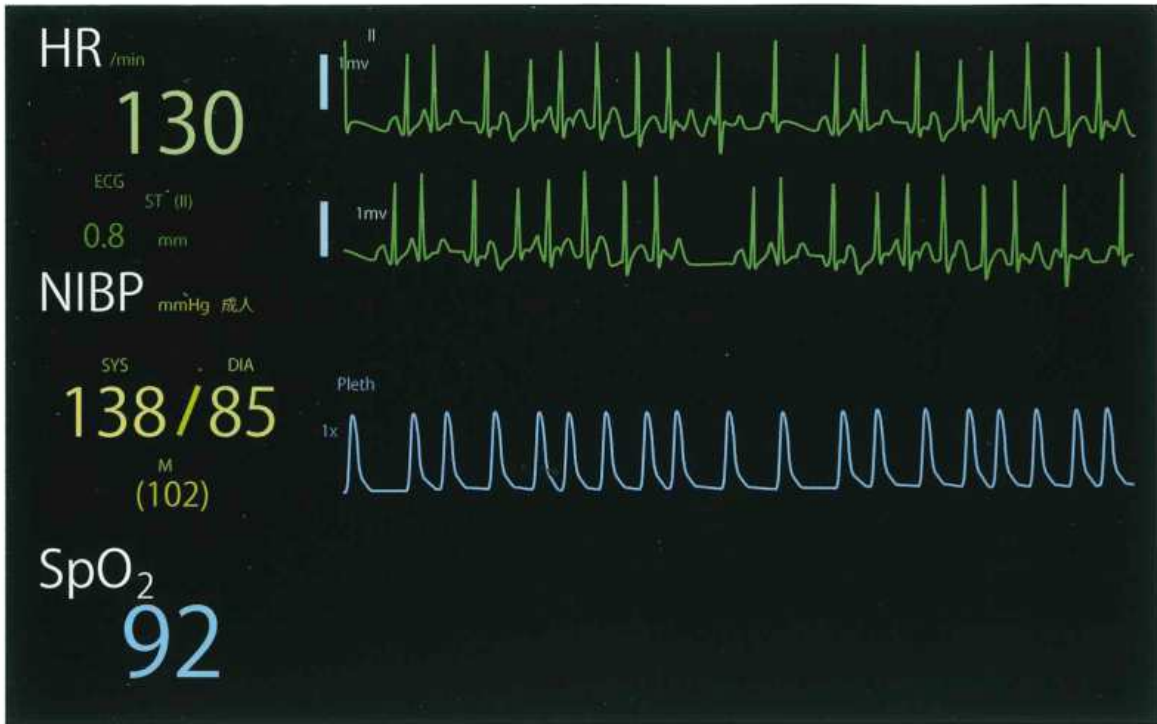(B 問題 70)

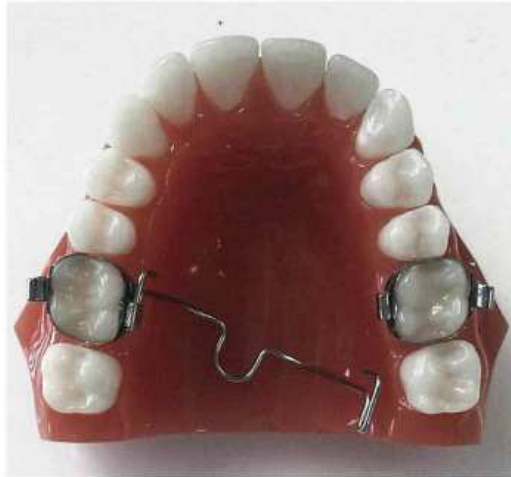A



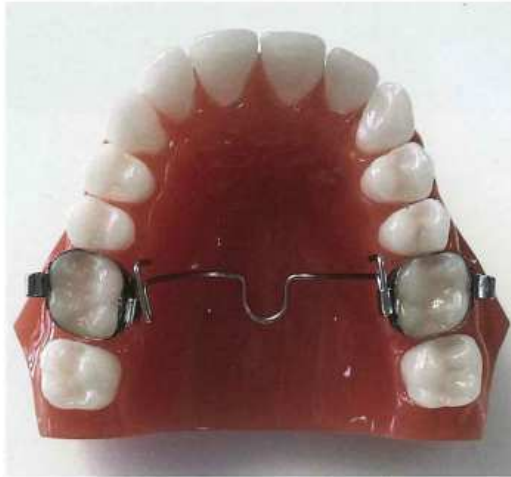B



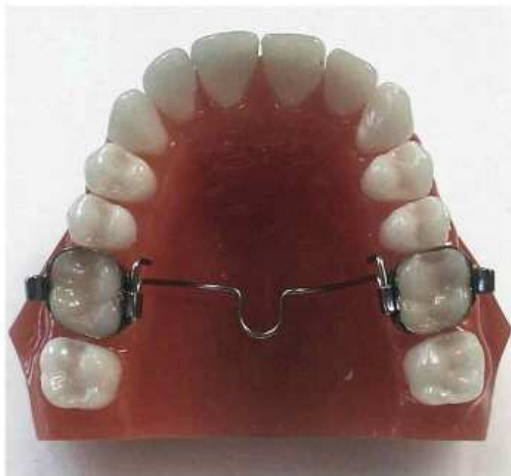



右側のみシース挿入時



左側のみシース挿入時



両側シース挿入時



No. 34

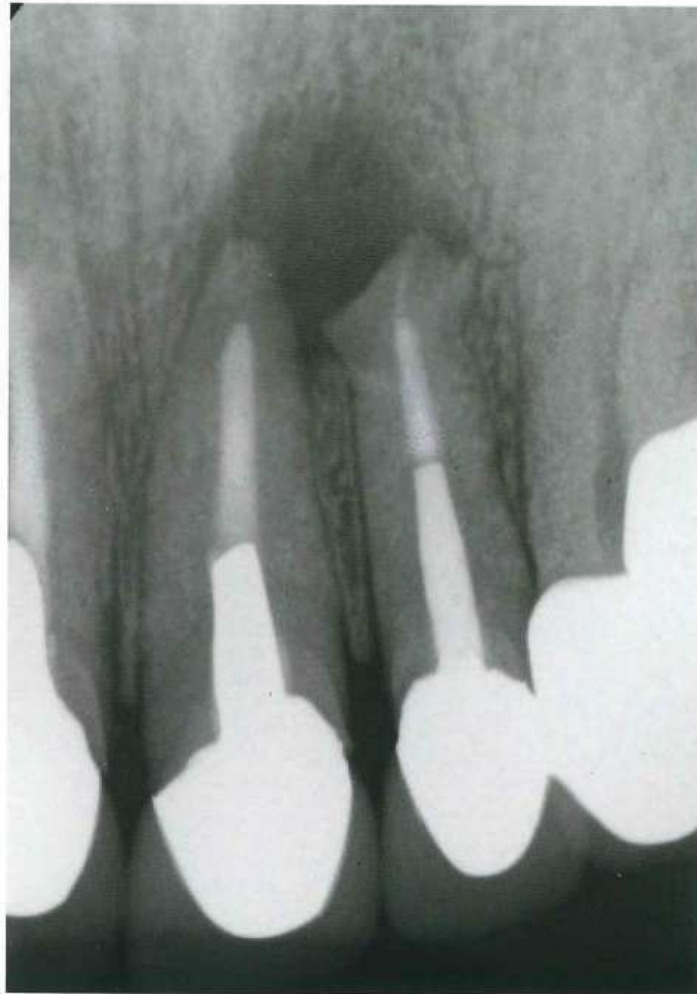
(B 問題 76)



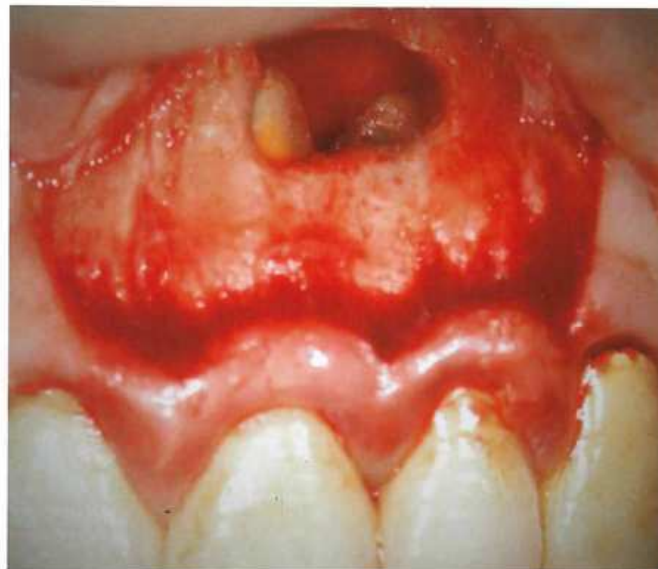No. 35

(B 問題 80)

A



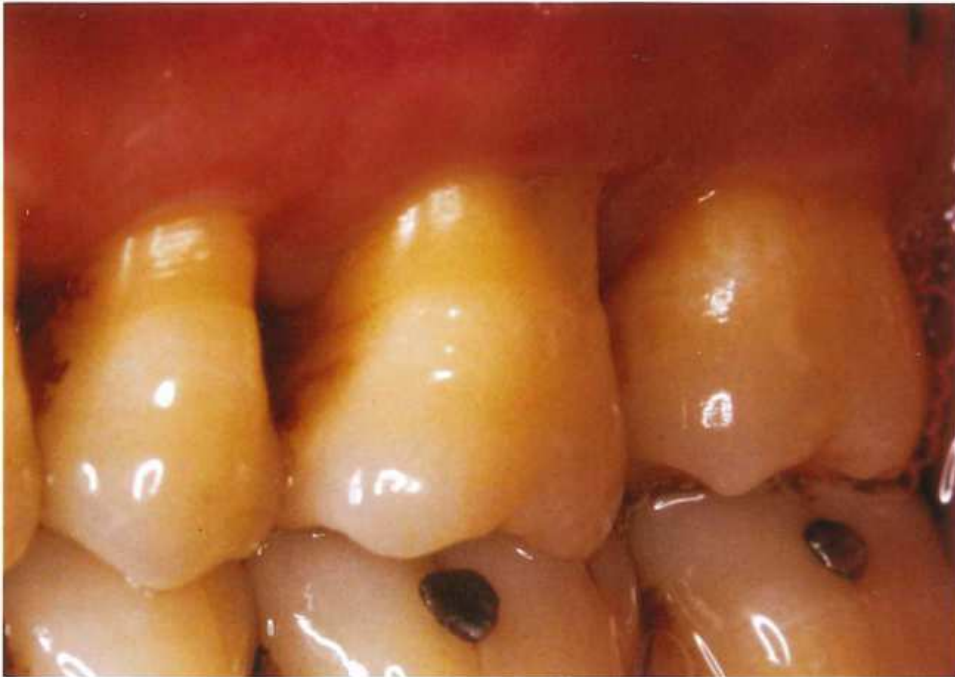B



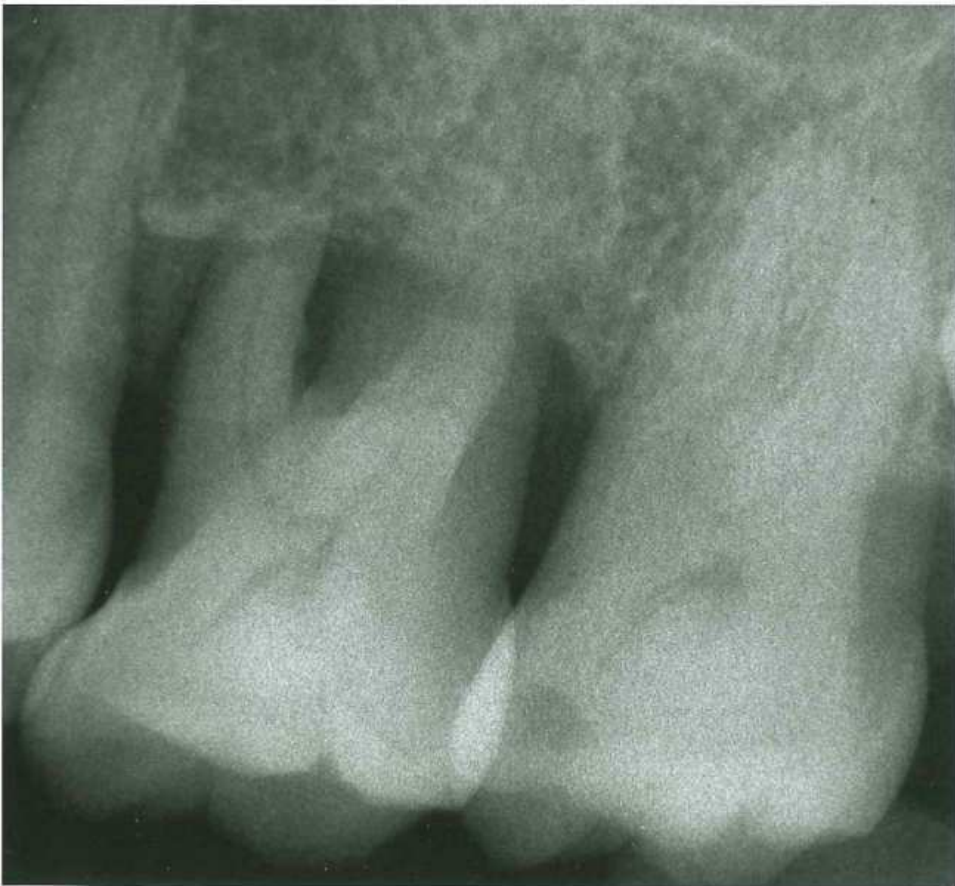No. 36

(B 問題 81)

A



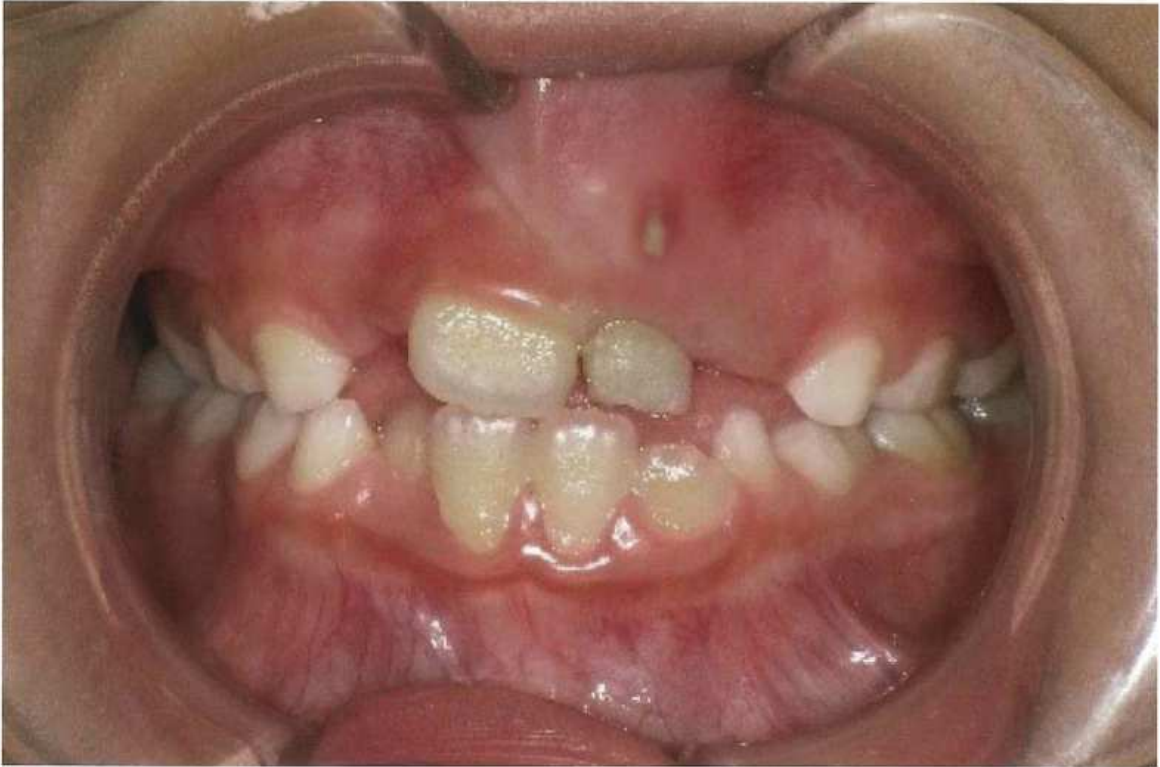B



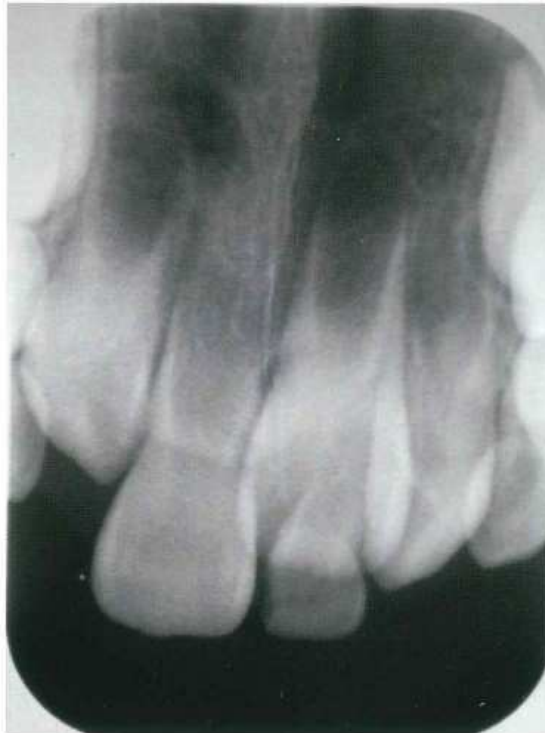No. 37

(B 問題 82)

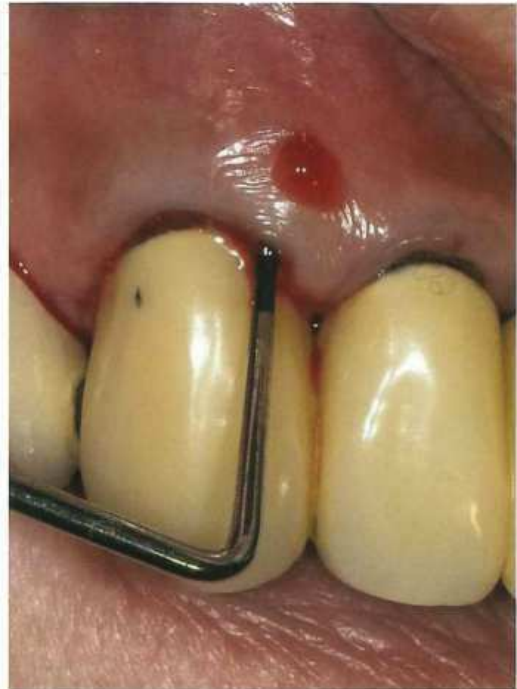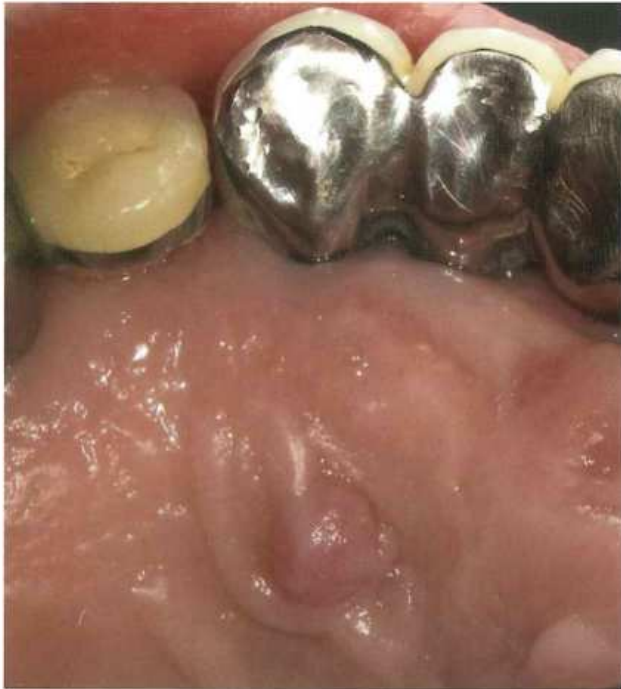A



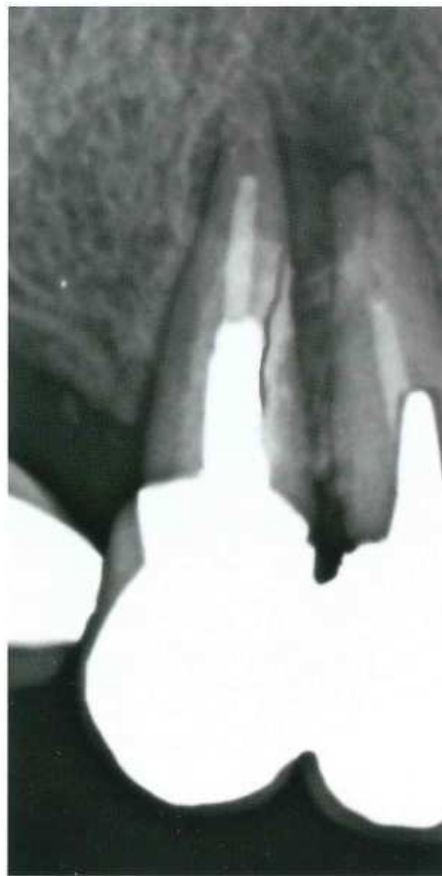B



A

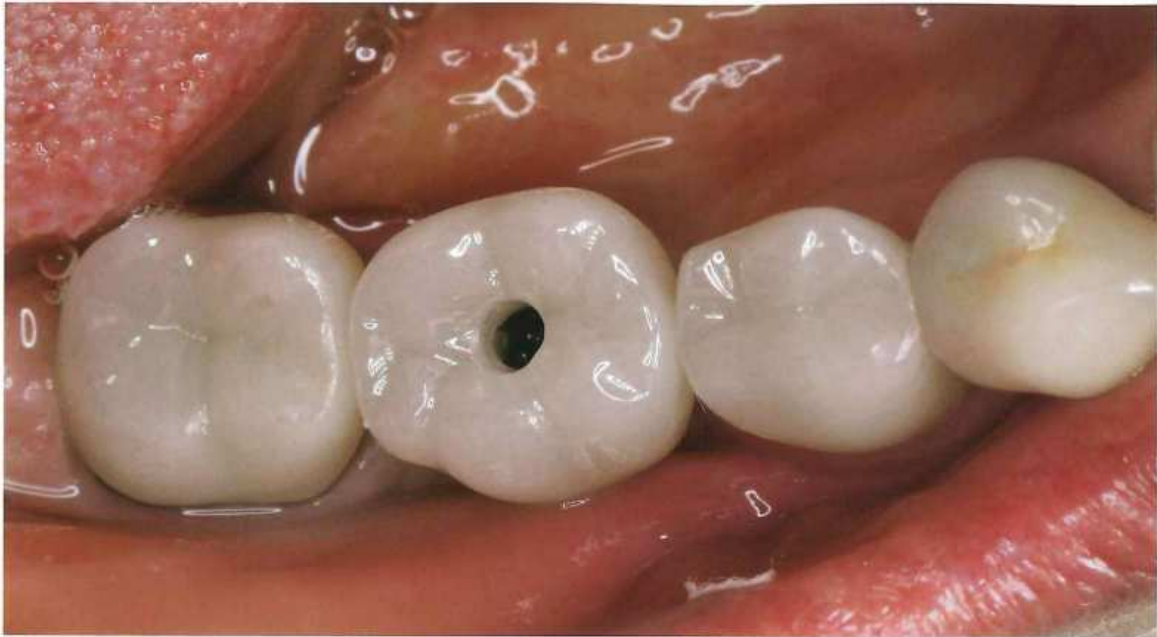

B





A



B

